

Transforaminal Lumbar Interbody Fusion with Expandable Interbody Device Provides Indirect Decompression through Significant Disc Height Restoration

Jonathon B Gentry¹, Son Le¹, Jessica R Riggleman^{2*}, Samantha L Greeley², Leigh Ahrendtsen² and Charles Ledonio²

¹Southwest Neuroscience & Spine Center, 11 Medical Drive, Amarillo, TX, USA

²Musculoskeletal Education and Research Center (MERC), A Division of Globus Medical, Inc., 2560 General Armistead Avenue, Audubon, PA 19403, USA

Abstract

Background: Achieving and maintaining indirect decompression is critical to the success of open transforaminal lumbar interbody fusion (O-TLIF) because it directly correlates with improved patient outcomes. This has led to significant advancements in interbody design. Expandable interbody devices have been developed to optimize the restoration of disc height, neuroforaminal height, and lordosis while minimizing endplate disruption.

Objective: The objective of this study is to quantify the radiographic outcomes of patients who underwent O-TLIF using an expandable interbody spacer.

Methods: Single-surgeon, retrospective, Institutional Review Board-exempt chart review of 68 consecutive patients who underwent O-TLIF at 1–2 contiguous level(s) using expandable interbody spacers. Radiographic outcomes were collected and compared at preoperative and postoperative timepoints up to 12 months. Statistical results were significant if $P < 0.05$.

Results: Over a three-year period, 68 consecutive patients underwent O-TLIF with a titanium expandable interbody spacer. The patients were 48.5% (33/68) female and 51.5% (35/68) male, with an average age of 52.6 ± 12.7 years. Mean anterior and posterior disc heights significantly improved by 3.8 ± 2.6 mm and 3.0 ± 2.5 mm, respectively, at 12 months (all $P < 0.001$). Mean neuroforaminal height significantly improved by 2.9 ± 3.9 mm at 12 months ($P < 0.001$). Mean intervertebral angle significantly improved by $1.4 \pm 4.0^\circ$ at 12 months ($P = 0.002$). Mean pelvic incidence minus lumbar lordosis mismatch significantly decreased by $2.3 \pm 8.4^\circ$ at 12 months ($P = 0.035$).

Conclusion: Anterior and posterior disc height, neuroforaminal height, and intervertebral angles were restored, providing evidence of indirect decompression. Segmental and lumbar lordosis was sustained. Expandable technology proved to be effective in the studied patients when used in an O-TLIF technique.

Keywords: Expandable; Fusion; Open Transforaminal Lumbar Interbody Fusion (O-TLIF)

Introduction

Open transforaminal lumbar interbody fusion (O-TLIF) is a popular method of treating patients with back and leg pain who have failed conservative management. Compared to anterior and lumbar interbody fusion procedures, O-TLIF allows the interbody device to be placed through a unilateral opening which is separated from vascular structures. Achieving and maintaining indirect decompression is critical to the success of the O-TLIF procedure because it directly correlates with improved patient outcomes [1]. Therefore, the restoration of disc height, neuroforaminal height, and lordosis are essential for adequate indirect decompression [2]. Numerous interbody spacer designs exist; the most common type used is a static interbody spacer. To achieve adequate indirect decompression, large interbody spacers are used to restore disc height and lordosis; however, adequate nerve root retraction and aggressive intervertebral endplate preparation are needed to fit large spacers. Expandable spacer technology for O-TLIF is designed to be inserted in a collapsed state and expanded *in situ*. The objective of this study is to determine the radiographic outcomes of patients who underwent O-TLIF using an expandable interbody spacer.

Method

This is a single-surgeon, retrospective, chart review of consecutive patients diagnosed with symptomatic degenerative disc disease (DDD) and/or Grade 1 spondylolisthesis in 1 or 2 contiguous levels, who underwent O-TLIF using an expandable titanium interbody spacer (RISE[®], Globus Medical, Inc. Audubon, PA) with supplemental fixation

(Figures 1, 2 and 3). Patient demographics and radiographic parameters were collected at 2 weeks, 6 weeks, 3, 6, and 12 months postoperatively. Institutional Review Board exemption was granted and patient consent was not required for this chart review.

Surgical technique

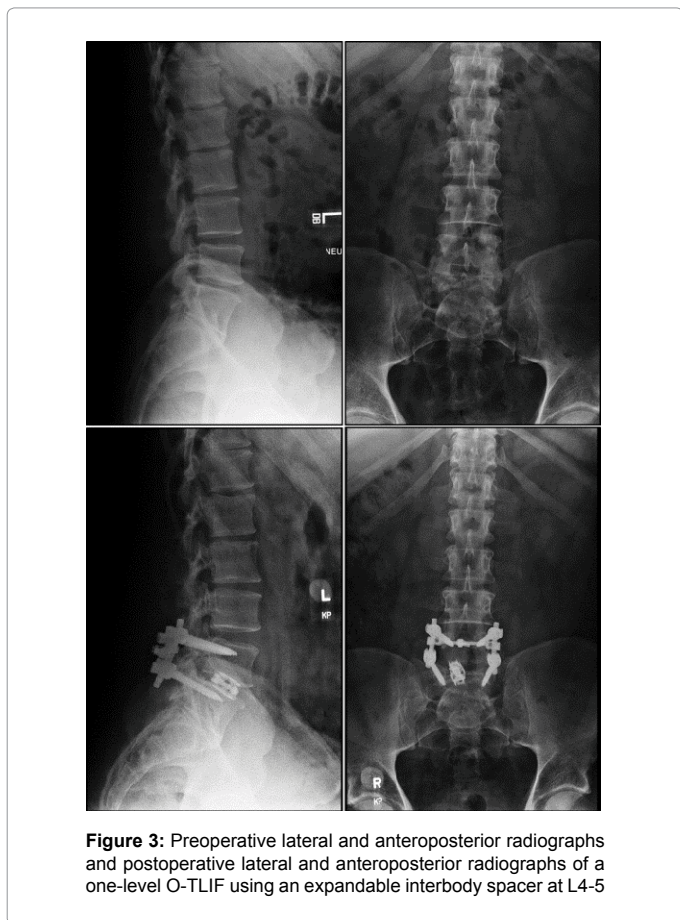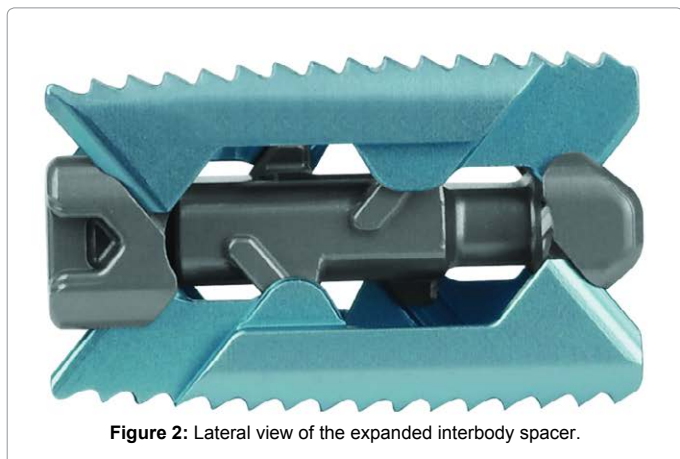
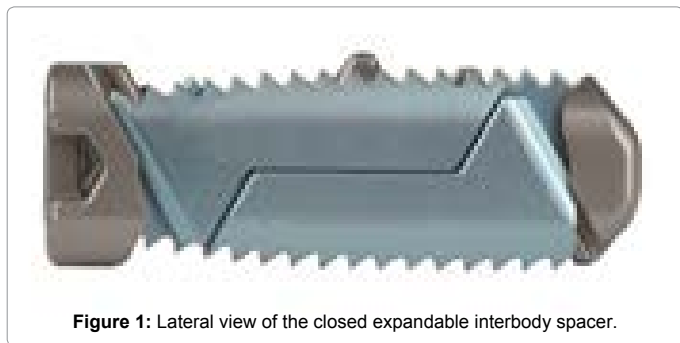
Under general anesthesia, the patient was placed prone on a Jackson table. Fluoroscopic scans were taken to map out skin incisions. The surgical area was prepped and draped following asepsis and antisepsis standard practices. Pedicle starting points were identified under fluoroscopic guidance. Pedicle screws of appropriate size were then placed after tapping was completed. Next, a unilateral facetectomy was completed and the posterior annulus was exposed with careful retraction of the nerve roots using the operating microscope. After annulotomy, a thorough discectomy was completed and the endplates were prepared. An expandable interbody spacer of appropriate size was then selected and implanted in the disc space under fluoroscopic

*Corresponding author: Jonathon B. Gentry, Southwest & Neuroscience & Spine Center, 11 Medical Drive, Amarillo, TX, USA, Tel: +1 806-353-6400; E-mail: jon.brettgentry@fmclp.com

Received October 14, 2019; Accepted October 29, 2019; Published November 04, 2019

Citation: Gentry JB, Le S, Riggleman JR, Greeley SL, Ahrendtsen L, et al. (2019) Transforaminal Lumbar Interbody Fusion with Expandable Interbody Device Provides Indirect Decompression through Significant Disc Height Restoration. J Spine 8: 440.

Copyright: © 2019 Gentry JB, et al. This is an open-access article distributed under the terms of the Creative Commons Attribution License, which permits unrestricted use, distribution, and reproduction in any medium, provided the original author and source are credited.



guidance. The target placement for the cage prior to expansion was as anteriorly as the patient anatomy safely allows which is about 2/3 of disc space. Occasionally, interbody spacers can settle in the middle of the disc space due to patient specific anatomy. The spacer was expanded with fluoroscopic guidance until the desired height was achieved. Autogenous bone graft was packed in the empty disc space around the spacer. Lordotically contoured rods were then placed. Pedicle screws were compressed and locking caps were tightened (Figure 4).

Implant description

The expandable interbody spacers used in this study are manufactured from titanium alloy. The device is inserted at a contracted height and expanded *in situ* once correctly positioned within the intervertebral space, offering continuous expansion for optimal endplate-to-endplate contact.

Quantitative measurements

Radiographic lumbosacral parameters were measured on upright lateral radiographs using imaging software (Surgimap[®], Globus Medical, Inc.) (Figure 5). Measurements taken included anterior and posterior disc heights, neuroforaminal height, intervertebral angle, segmental lordosis, and lumbar lordosis. Disc height was defined as the distance between the inferior and superior endplates at the anterior and posterior portions of the vertebral body. Neuroforaminal height refers to the interpedicular height, or the rostral and caudal boundaries of the foramen. The intervertebral angle was measured between the inferior endplate of the upper vertebra and the superior endplate of the lower vertebra. Segmental lordosis was measured as the Cobb angle of the inferior endplate of the level below the TLIF and the superior endplate of the level above the TLIF. Lumbar lordosis was measured as the angle between the superior endplate of L1 and the superior endplate of S1. Pelvic incidence was measured as “the angle between the perpendicular line to the sacral plate at its midpoint and the line connects this point to the middle axis of the femoral heads,” as previously described [3]. The pelvic incidence lumbar lordosis (PI-LL) mismatch was calculated as the pelvic incidence minus the lumbar lordosis.

Statistical analysis

The statistical analysis was performed using IBM[®] SPSS[®] Version 25 software (IBM[®] Corp.; Armonk, NY). Descriptive statistics are presented as means, standard deviations, frequencies and percentages. Radiographic measurements are presented as means and standard deviations. The effects of O-TLIF using an expandable interbody spacer were calculated using paired t-tests. Statistical significance was indicated at $P < 0.05$.

Results

Patient demographics

From January 2013 to January 2016, 68 consecutive patients underwent O-TLIF with a titanium expandable interbody spacer. The patients were 48.5% (33/68) female and 51.5% (35/68) male, with an average age of 52.6 ± 12.7 years (Range: 23–80 years). Twenty-five percent of patients were smokers at the time of surgery. Forty-eight percent of patients received steroid injections prior to surgery. Patients were diagnosed with either degenerative spondylolisthesis [61.8% (42/68)] or DDD [38.2% (26/68)] (Table 1). Implant height and lordosis varies for each patient and level. All implants used were 10 mm in width and either 22 mm or 26 mm in length.

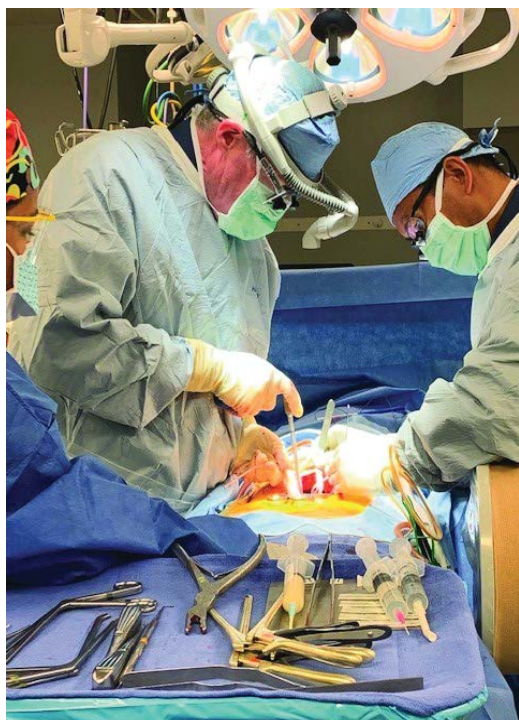

Figure 4: Open transforaminal lumbar interbody fusion.

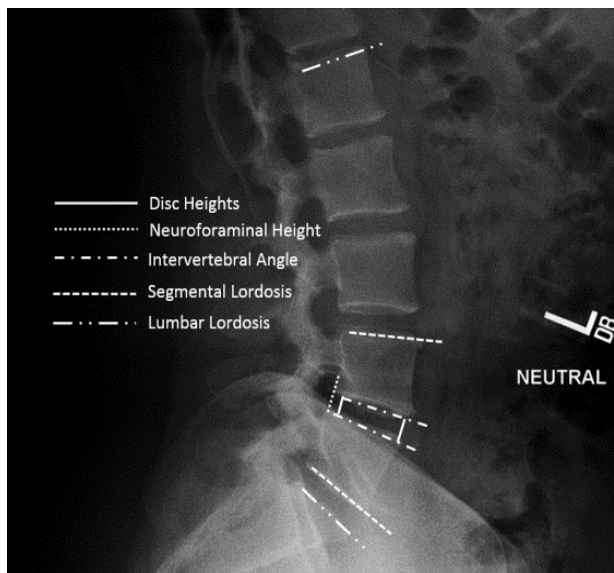


Figure 5: Standing lateral lumbar spine radiograph with superimposed lines displaying the measurements evaluated in this study. Measurements included disc heights, neuroforaminal height, intervertebral angle, segmental lordosis and lumbar lordosis.

Surgical data

Of the 68 patients, 72.1% (49/68) underwent one-level and 27.9% (19/68) underwent two-level O-TLIF, for a total of 87 spinal levels treated. Of the 87 levels, 48.3% (42/87) were performed at L5–S1 and 44.8% (39/87) at L4–L5. The average estimated blood loss was 186.6 ± 135.9 cc for one-level fusions and 191.8 ± 136.6 cc for two-level fusions

with no blood transfusions (Table 2).

Radiographic parameters

The mean anterior disc height significantly improved by 4.9 ± 3.4 mm (50.5%), 4.6 ± 3.6 mm (48.5%), 4.7 ± 3.5 mm (51.5%), 3.9 ± 3.6 mm (45.5%), and 3.8 ± 2.6 mm (38.4%) at 2 weeks, 6 weeks, and 3, 6, and 12 months, respectively (all $P < 0.001$). The mean posterior disc height significantly improved by 3.5 ± 2.0 mm (67.9%), 3.3 ± 2.0 mm (60.4%), 3.2 ± 2.0 mm (64.2%), 3.2 ± 2.2 mm (60.4%), and 3.0 ± 2.5 mm (58.5%) at 2 weeks, 6 weeks, and 3, 6, and 12 months, respectively (all $P < 0.001$). The mean neuroforaminal height significantly improved by 3.6 ± 4.2 mm (20.8%), 3.5 ± 3.8 mm (19.1%), 3.2 ± 3.6 mm (19.1%), 3.1 ± 3.9 mm (20.2%), and 2.9 ± 3.9 mm (16.8%) at 2 weeks, 6 weeks, and 3, 6, and 12 months, respectively (all $P < 0.001$) (Figure 6).

The mean intervertebral angle significantly improved by $2.2 \pm 4.2^\circ$ (27.6%; $P < 0.001$), $1.7 \pm 4.3^\circ$ (28.9%; $P = .001$), $1.7 \pm 4.2^\circ$ (26.3%; $P = 0.002$), $1.3 \pm 4.0^\circ$ (28.9%; $P = 0.01$), $1.4 \pm 4.0^\circ$ (17.1%; $P = 0.002$) at 2 weeks, 6 weeks, and 3, 6, and 12 months, respectively. The mean segmental lordosis significantly improved by $2.6 \pm 5.0^\circ$ (14.5%; $P < 0.001$), $2.1 \pm 5.3^\circ$ (10.6%; $P = 0.001$), and $2.0 \pm 4.8^\circ$ (11.7%; $P = 0.002$)

Parameters	Overall
Number of Patients	68
Sex	
Female, n (%)	33 (48.5%)
Male, n (%)	35 (51.5%)
Age, mean (SD, range)	52.6 (12.7) (23–80)
BMI, mean (SD, range)	32.4 (5.5) (19–46)
Smoker, n (%)	
Current	17 (25.4%)
Former/Never	50 (74.6%)
Steroid Injections, n (%)	
Yes	29 (48.3%)
No	31 (51.7%)
Diagnosis, n (%)	
Degenerative Spondylolisthesis	42 (61.8%)
Degenerative Disc Disease	26 (38.2%)

Table 1: Baseline characteristics.

Parameters	Overall
Type of Surgery, n (%)	
One-level	49 (72.1%)
Two-level	19 (27.9%)
Levels Treated, n (%)	
L2–L3	1 (1.1%)
L3–L4	5 (5.7%)
L4–L5	39 (44.8%)
L5–S1	42 (48.3%)
Mean Estimated Blood Loss, n (SD)	
One-level	186.6 (135.9)
Two-level	191.8 (136.6)

Table 2: TLIF surgical data.

at 2 weeks, 6 weeks, and 3 months, respectively. The mean segmental lordosis improved by $1.0 \pm 4.9^\circ$ (7.3%; $P=0.11$) at 6 months and $0.7 \pm 4.6^\circ$ (3.9%; $P=0.17$) at 12 months, respectively, but the differences were not significant. The mean lumbar lordosis improved by $0.9 \pm 9.2^\circ$ (2.0%; $P=0.41$), $1.7 \pm 8.8^\circ$ (0.2%; $P=0.16$), $1.0 \pm 8.7^\circ$ (0.7%; $P=0.44$), $1.7 \pm 8.2^\circ$ (2.4%; $P=0.16$), and $2.0 \pm 8.4^\circ$ (4.4%; $P=0.05$) at 2 weeks, 6 weeks, and 3, 6, and 12 months, respectively, but the differences were not significant. The mean PI-LL mismatch decreased by $0.9 \pm 9.2^\circ$ (8.6%; $P=0.47$), $2.4 \pm 8.8^\circ$ (16.1%; $P=0.07$), $1.2 \pm 8.5^\circ$ (14.5%; $P=0.36$), $2.4 \pm 8.2^\circ$ (23.9%; $P=0.07$), $2.3 \pm 8.4^\circ$ (22.3%; $P=0.035$) at 2 weeks, 6 weeks, and 3, 6, and 12 months, respectively. The difference from baseline was only significant at 12 months (Table 3).

Complications

There were no reported implant-related complications, radiolucency, or subsidence by 12-month follow-up. There were no reported incidences of postoperative radicular leg pain.

Discussion

Radiographic outcomes are essential to providing evidence on the use of expandable interbody spacers to restore disc and neuroforaminal height, resulting in indirect decompression. To the best of the authors' knowledge, this is the second study to describe the radiographic outcomes of the use of an expandable interbody spacer in O-TLIF, therefore comparison to the literature is challenging. A search was done on Pubmed to include the following keywords: (expandable [All Fields] and open [All Fields]) and transforaminal [All Fields]) and ("lumbosacral region" [MeSH Terms] or ("lumbosacral" [All Fields]

and "region" [All Fields]) or "lumbosacral region" [All Fields] or "lumbar" [All Fields]) and interbody [All Fields]) and ("Nucl Eng Des/Fusion" [Journal] or "FUSION" [Journal] or "fusion" [All Fields]). The search resulted in 17 articles, in which one study reported clinical and radiographic outcomes for O-TLIF using expandable spacers. The study by Boktor et al. included 54 patients, with a total of 62 levels. The current study investigated the radiographic outcomes of patients who underwent O-TLIF with expandable interbody spacers with a larger patient population than previously reported [4].

In TLIFs, bilateral pedicle screw augmentation offers significant biomechanical stability of the spinal segment [5]. Clinically, the few studies that report radiographic outcomes on expandable interbody spacers either have a small sample size or show inconsistent results. Hawasli et al. [6] conducted a single-center retrospective review analyzing clinical and radiographic results of two cohorts using the minimally invasive (MIS) TLIF technique: 28 patients treated with an articulating expandable interbody device and 16 patients treated with a static interbody device. Radiographic measurements were taken at two time points: immediately postoperatively and at the final follow-up (a mean of 7.1 months for expandable, 14.6 months for static). The authors report that MIS TLIF with an expandable interbody device allows an increase in anterior disc height over time, while neuroforaminal height only increases immediately postoperative. The study also reported an immediate increase in segmental lordosis, but no effects on overall lumbar lordosis.

Similarly, in the current study, anterior disc height significantly increased at all-time points compared to baseline. Specifically, it

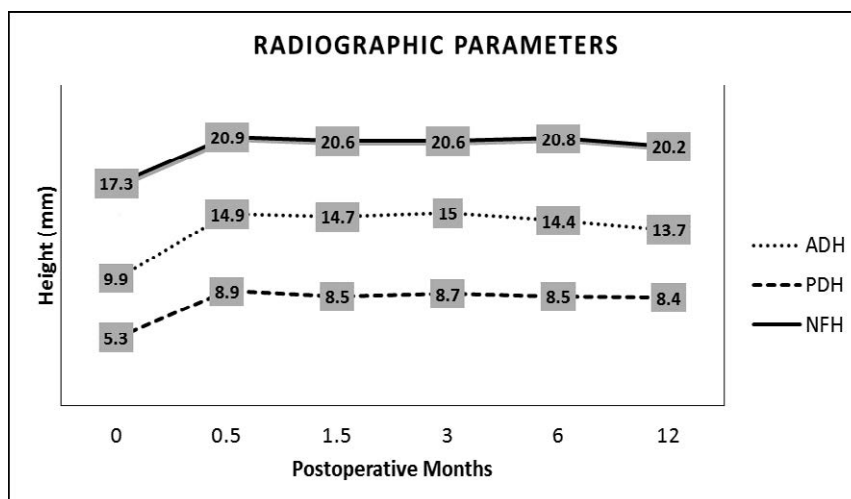


Figure 6: Mean radiographic measurements are shown. The results showed a significant increase from baseline for each parameter that was sustained at 0.5, 1.5, 3, 6, and 12 months. [ADH=Anterior Disc Height; PDH=Posterior Disc Height; NFH=Neuroforaminal Height].

Parameters	Baseline	2 Weeks	6 Weeks	3 Months	6 Months	12 Months
Anterior Disc Height (mm)	9.9 (3.8)	14.9 (3.0)*	14.7 (2.9)*	15.0 (2.5)*	14.4 (2.7)*	13.7 (2.8)*
Posterior Disc Height (mm)	5.3 (2.3)	8.9 (1.8)*	8.5 (1.7)*	8.7 (1.6)*	8.5 (2.0)*	8.4 (1.9)*
Neuroforaminal Height (mm)	17.3 (5.4)	20.9 (4.6)*	20.6 (4.0)*	20.6 (4.1)*	20.8 (3.8)*	20.2 (3.8)*
Intervertebral Angle (°)	7.6 (4.7)	9.7 (4.5)*	9.8 (4.4)*	9.6 (4.3)*	9.8 (4.2)*	8.9 (3.9)*
Segmental Lordosis (°)	17.9 (7.2)	20.5 (7.6)*	19.8 (7.0)*	20.0 (7.5)*	19.2 (7.2)	18.6 (6.5)
Lumbar Lordosis (°)	45.2 (15.0)	46.1 (11.1)	45.3 (11.1)	45.5 (12.9)	46.3 (11.9)	47.2 (12.4)
PI-LL (°)	10.5 (12.4)	9.6 (9.3)	8.8 (9.6)	9.0 (10.5)	8.0 (8.9)	8.1 (10.0)*

Table 3: Mean values of radiographic parameters
* $P<0.05$ compared to baseline.

increased by 50.5% at 2 weeks and by 38.4% at 12-month follow-up. This supports the notion that expandable interbody devices provide the benefit of indirect decompression of the nerve roots by producing significant restoration of disc height. In the current study, posterior disc height also significantly increased at all postoperative time points compared to baseline, increasing by 67.9% at 2-week follow-up and by 58.5% at 12-month follow-up.

In the previously described study [6], MIS TLIF with an expandable interbody spacer increased neuroforaminal height only immediately postoperative; the increase was not sustained. This is in contrast to the current study, where neuroforaminal height significantly increased by 20.8% at 2 weeks and by 16.8% at 12-month follow-up. This supports the concept that expandable interbody devices provide indirect decompression of the nerve roots by producing a significant increase in neuroforaminal height not only immediately postoperatively, but also at later follow-up.

In a similar retrospective consecutive case series by Kim et al. [7] a significant increase in intervertebral disc height from baseline to immediate postoperative (49.4%) and 12 months postoperative (43.4%) was reported. These results are consistent with the current study, where intervertebral disc height increased by 50.5% at 2 weeks and 38.4% by 12-month follow-up. In the same study, 10.3% and 4.0% increases from baseline to immediate postoperative and 12 months postoperative, respectively, were reported in neuroforaminal height [7]. This is similar to the current study, where neuroforaminal height significantly increased by 20.8% at 2 weeks and by 16.8% at 12-month follow-up. Similar increases in segmental lordosis were apparent. Kim et al. [7] reported an increase of 13.2%, while the current study found a 14.5% increase in segmental lordosis at 2 weeks. Kim et al. [7] reported a 6.6% increase, while the present study found a 3.9% increase at 12 months in lumbar lordosis.

In the current study, lumbar lordosis increased by 2.0%, 0.2%, 0.7%, 2.4%, and 4.4% at 2 weeks, 6 weeks, 3, 6, and 12 months, respectively ($P > 0.05$). According to the literature, the normal range of lumbar lordosis is from 30°–80° [8-10]. In the current study, 86.8% (59/68) patients fell within the normal range of 30°–80° for lumbar lordosis when measured preoperatively. At 12 months, 88.2% (60/68) patients fell within the normal range for lumbar lordosis. Because lumbar lordosis was considered normal in the majority of the patients preoperatively and postoperatively, the results did not show a significant increase from baseline to postoperative.

PI-LL is an important spinopelvic radiological parameter when planning surgeries and predicting postoperative pain and disability. A PI-LL of less than or equal to 10° is ideal for reducing postoperative pain [11]. In the current study the baseline PI-LL mismatch was $10.5 \pm 12.4^\circ$, significantly decreasing to $8.1 \pm 10.0^\circ$ by 12 months postoperative. Aoki et al. demonstrated that PI-LL mismatch significantly correlated with surgical outcomes after short-segment lumbar interbody fusion, therefore surgical outcomes following surgery will be poorer when good spinopelvic balance is not achieved [12]. Our results show that PI-LL mismatch was ideal postoperatively.

Expandable spacers has the advantage of being placed in a minimized height followed by *in situ* expansion, which diminishes endplate damage by requiring less insertion force than static spacers. A surgeon using expandable spacers is likely to monitor expansion radiographically, reducing the potential over-distraction of the disc space, which has been directly correlated to adjacent segment disease following posterior lumbar fusion [13,14]. Adequate placement of a TLIF spacer is just as important to surgical success as the reduction of insertion force and disc space distraction.

Study limitations

Although this is a single-surgeon, single-site, retrospective study without comparison to a cohort, the results are consistent with findings from the literature. According to Obremsky et al. [15], a well-executed orthopaedic study of this nature includes a patient population for which a standard treatment protocol is used, a follow-up rate of >80%, and follow-up of patients at specified time-intervals, all of which this study has met. This study forms the foundation for future studies with a higher level of evidence. Comparative studies with larger sample sizes and longer follow-up are needed to determine the effectiveness of O-TLIF using an expandable interbody spacer versus traditional treatment. To further study surgical outcomes and sagittal alignment, clinical full length standing radiographs will be required to study sagittal and coronal spinal balance in the future.

Conclusion

O-TLIF using an expandable titanium interbody spacer improved radiographic outcomes in this cohort. Anterior and posterior disc height, neuroforaminal height, and intervertebral angle were significantly restored, providing evidence of indirect decompression.

Sources of Funding

Funding for this project was provided by the Musculoskeletal Education and Research Center (MERC), a Division of Globus Medical, Inc.

References

1. Xie L, Wu WJ, Liang Y (2016) Comparison between minimally invasive transforaminal lumbar interbody fusion and conventional open transforaminal lumbar interbody fusion: An updated meta-analysis. Chin Med J (Engl) 129: 1969-1986.
2. Guigui P, Ferrero E (2017) Surgical treatment of degenerative spondylolisthesis. OTSR 103: S11-S20.
3. Legaye J, Duval-Beaupere G, Hecquet J, Marty C (1998) Pelvic incidence: a fundamental pelvic parameter for three-dimensional regulation of spinal sagittal curves. Eur Spine J. 7: 99-103.
4. Boktor JG, Pockett RD, Verghese N (2018) The expandable transforaminal lumbar interbody fusion - Two years follow-up. J Craniovertebr Junction Spine 9: 50-55.
5. Schleicher P, Beth P, Ottenbacher A, Pflugmacher R, Scholz M, et al. (2008) Biomechanical evaluation of different asymmetrical posterior stabilization methods for minimally invasive transforaminal lumbar interbody fusion. J Neurosurg Spine 9: 363-371.
6. Hawasli AH, Khalifeh JM, Chatrath A, Yarbrough CK, Ray WZ (2017) Minimally invasive transforaminal lumbar interbody fusion with expandable versus static interbody devices: Radiographic assessment of sagittal segmental and pelvic parameters. Neurosurg Focus 43: E10.
7. Kim CW, Doerr TM, Luna IY, Joshua G, Shen SR, et al. (2016) Minimally invasive transforaminal lumbar interbody fusion using expandable technology: A clinical and radiographic analysis of 50 patients. World Neurosurg 90: 228-235.
8. Been E, Kalichman L (2014) Lumbar lordosis. Spine J 14: 87-97.
9. Gelb DE, Lenke LG, Bridwell KH, Blanke K, McEnery KW (1995) An analysis of sagittal spinal alignment in 100 asymptomatic middle and older aged volunteers. Spine (Phila Pa 1976) 20: 1351-1358.
10. Vedantam R, Lenke LG, Keeney JA, Bridwell KH (1998) Comparison of standing sagittal spinal alignment in asymptomatic adolescents and adults. Spine (Phila Pa 1976) 23: 211-215.
11. Schwab FJ, Blondel B, Bess S, Hostin R, Shaffrey CI, et al. (2013) Radiographical spinopelvic parameters and disability in the setting of adult spinal deformity: A prospective multicenter analysis. Spine (Phila Pa 1976) 38: E803-E812.

-
12. Aoki Y, Nakajima A, Takahashi H, Sonobe M, Terajima F, et al. (2015) Influence of pelvic incidence-lumbar lordosis mismatch on surgical outcomes of short-segment transforaminal lumbar interbody fusion. BMC Musculoskelet Disord. 16: 213.
 13. Kaito T, Hosono N, Mukai Y, Makino T, Fuji T, et al. (2010) Induction of early degeneration of the adjacent segment after posterior lumbar interbody fusion by excessive distraction of lumbar disc space. Journal of neurosurgery Spine 12: 671-679.14.
 14. Torretti J, Harris JA, Bucklen BS, Moldavsky M, Khalil SED (2018) *In vitro* biomechanical and fluoroscopic study of a continuously expandable interbody spacer concerning its role in insertion force and segmental kinematics. Asia Spine J 12: 601-610.
 15. Obremskey WT, Pappas N, Attallah-Wasif E, Tornetta P, Bhandari M (2005) Level of evidence in orthopaedic journals. J Bone Joint Surg Am 87: 2632-2638.

PAGE INTENTIONALLY LEFT BLANK

