

Laterally Placed Expandable Interbody Spacers with Adjustable Lordosis Improve Radiographic and Clinical Outcomes

Yan Michael Li^{1*}, Zheng Huang², James Towner¹, Yan Icy Li¹, Jessica R. Riggleman³ and Charles G. Ledonio³

¹Department of Neurosurgery and Oncology, Medical Center School of Medicine and Dentistry, University of Rochester, New York, USA

²Department of Orthopaedics, Guanghua Hospital, P.R. China

³Musculoskeletal Education and Research Center, A Division of Globus Medical Inc., Audubon, Pennsylvania, USA

Abstract

Introduction: Minimally invasive lateral lumbar interbody fusion (MIS LLIF) has been shown to minimize soft tissue dissection and blood loss in comparison to open posterior lumbar interbody fusion. This study describes the clinical and radiographic outcomes of patients treated with expandable interbody spacers with adjustable lordosis for MIS LLIF.

Methods: This is a single surgeon retrospective Institutional Review Board-exempt chart review on 57 consecutive patients who underwent MIS LLIF at 1–2 contiguous level(s) using expandable spacers with adjustable lordosis, which allow for expansion in height and lordosis. Radiographic and clinical functional outcomes were collected and compared at preoperative and postoperative time points up to 12 months. Statistical results were significant if $P < 0.05$.

Results: Fifty-seven consecutive patients were evaluated with an average age of 58 ± 12.3 years, and 49.1% were female. Visual Analog Scale (VAS) for back pain and Oswestry Disability Index (ODI) scores decreased significantly at 12 months ($P < 0.001$). Lumbar lordosis improved by a mean of 5.1° at 12 months ($P < 0.001$). Anterior, middle, and posterior disc height significantly increased at 12 months by means of 5.2 mm, 4.6 mm, and 2.6 mm respectively ($P < 0.001$). Neuroforaminal height increased by a mean of 3.7 mm ($P < 0.001$) while segmental lordosis improved by 3.7° at 12 months.

Discussion and Conclusion: This study showed significant positive clinical and radiographic outcomes for patients who underwent MIS LLIF using expandable interbody spacers with adjustable lordosis based on decreased VAS back pain and ODI scores at 1-year follow-up. The use of expandable spacers with adjustable lordosis was shown to be safe and effective for the cohort studied.

Keywords: Expandable; Fusion; LLIF; Minimally invasive; Lateral lumbar interbody fusion

Introduction

First described by Ozgur and co-authors in 2006, lateral lumbar interbody fusion (LLIF) is a popular retroperitoneal transpoas approach to access the disk space for lumbar spine interbody fusion [1]. The potential advantages of this approach include minimizing the risk of complications associated with either the anterior approach or the posterior approaches [2,3].

A critical component to the success of the lateral procedure is the interbody spacer, which can help to achieve sagittal correction. Since preservation or restoration of sagittal alignment is a significant predictor in determining patient outcomes, maximizing disc height, segmental lordosis, and achieving adequate indirect decompression is of the utmost importance [4-6]. Fusing the lumbar spine in a hypolordotic alignment predisposes the patient to development of adjacent segment disease (ASD) [7,8]. Consequently, postoperative sagittal plane abnormalities are correlated with ASD development [9].

There are many interbody spacer designs, some with built-in lordosis. The effects of increasing anterior lordosis without proportionally increasing disc height may have conflicting results. There are conflicting results in the literature on the effects of interbody spacer design with or without built-in lordosis on segmental lordosis [10]. Other interbody spacer designs that are highly lordotic could possibly present a challenge to insert in disc spaces that are collapsed. One of the advantages of an expandable spacer is that the spacer is delivered in a collapsed state and expanded *in-situ*. Developments in expandable technology now allow for cages to increase in both height and lordosis in a controlled expansion. Clinical outcome studies are needed to generate evidence of effectiveness and safety. The objective of this study is to determine the clinical and radiographic outcomes of patients who underwent MIS LLIF using an expandable interbody

spacer with an adjustable lordosis (RISE-AL[®] Globus Medical Inc. Audubon, PA) (Figures 1 and 2).



Figure 1: Oblique view of the titanium expandable interbody spacer with adjustable lordosis.

***Corresponding author:** Dr. Yan Michael Li, Neurosurgery and Oncology University of Rochester Medical Center School of Medicine and Dentistry Rochester NY, USA, Tel: +5856781198; E-mail: Dr.yanli@gmail.com

Received May 01, 2019; Accepted May 15, 2019; Published May 22, 2019

Citation: Li YM, Huang Z, Towner J, Li YI, Riggleman JR, et al. (2019) Laterally Placed Expandable Interbody Spacers with Adjustable Lordosis Improve Radiographic and Clinical Outcomes. J Spine S8: 001. doi:10.4172/2165-7939.S8-001

Copyright: © 2019 Li YM, et al. This is an open-access article distributed under the terms of the Creative Commons Attribution License, which permits unrestricted use, distribution, and reproduction in any medium, provided the original author and source are credited.

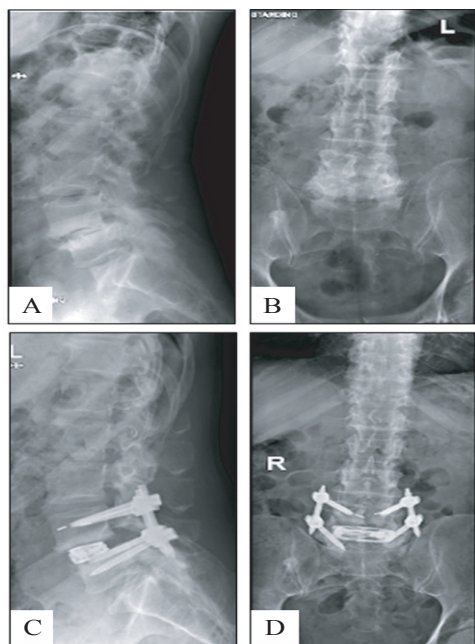


Figure 2: Preoperative lateral (A) and anteroposterior (B) radiographs and postoperative lateral (C) and anteroposterior (D) radiographs of a one-level MIS LLIF using an adjustable lordotic expandable interbody spacer at L4-L5.

Research Methodology

This is a retrospective study from a prospectively collected consecutive cohort of patients who were diagnosed with symptomatic degenerative disc disease with or without grade 1 spondylolisthesis in one or two contiguous levels and underwent MIS LLIF using a novel expandable interbody spacer with adjustable lordosis with supplemental fixation. Patient demographics, VAS back pain, ODI scores and radiographic parameters were collected at 6 weeks, 3, 6 and 12 months postoperatively.

Surgical technique

After induction of general anesthesia, patients were placed in the lateral decubitus position and secured to the operating table with adhesive medical tape. Under fluoroscopic guidance, an oblique incision was made at the operative disc segment. Blunt dissection was performed under direct visualization through the retroperitoneal space. Retroperitoneal fat was mobilized anteriorly, exposing the underlying psoas muscle. The psoas muscle was palpated, and blunt dissection was performed down to the operative intervertebral disc level. After confirmation of the appropriate level via fluoroscopy, a minimally invasive retractor was docked, dilated at the segment, and secured to the table-mounted arm. An annulotomy was then performed, followed by a discectomy. Under fluoroscopic imaging, the endplates were prepared.

An expandable trial was used to allow for gradual distraction of the disc space. An expandable interbody spacer manufactured from titanium alloy was selected, packed with autogenous bone graft, and implanted laterally across the disc space at a contracted height. The spacer was then expanded to the desired height *in situ* under fluoroscopic guidance and backfilled with autogenous bone graft (Figure 3). Pedicle screws and rods were used for supplemental fixation. Locking caps were set once the rods were in their proper position. Intraoperative fluoroscopy images were taken to verify the screw and rod position. Surgical incisions were cleaned and closed in the standard fashion.

Quantitative measurements

Radiographic lumbosacral parameters were measured on upright lateral radiographs using imaging software (Intellispace PACS 4.4©; Koninklijke Philips N.V, Amsterdam, Netherlands) (Figure 4). Measurements included disc heights, neuroforaminal height, segmental lordosis, and lumbar lordosis. Disc height was defined as the distance between the inferior and superior endplates at the anterior, middle, and posterior portions of the vertebral body. Neuroforaminal height refers to the interpedicular height, or the rostral and caudal boundaries of the foramen. Segmental lordosis was measured as the Cobb angle of the superior endplate of the level below the LLIF and the inferior endplate of the level above the LLIF. Lumbar lordosis was measured as the angle between the superior endplate of L1 and the superior endplate of S1.

Statistical analysis

The statistical analysis was performed using IBM® SPSS® Version 25 (IBM® Corp.; Armonk, NY, USA). Descriptive statistics are presented as frequencies and percentages. Clinical and radiographic measurements are presented as means and standard deviations. Statistical significance was shown at $P < 0.05$.

Results

Patient demographics

A total of 57 consecutive patients underwent MIS LLIF from August 2016 to November 2017, and were implanted with a titanium expandable interbody spacer with adjustable lordosis. The patients

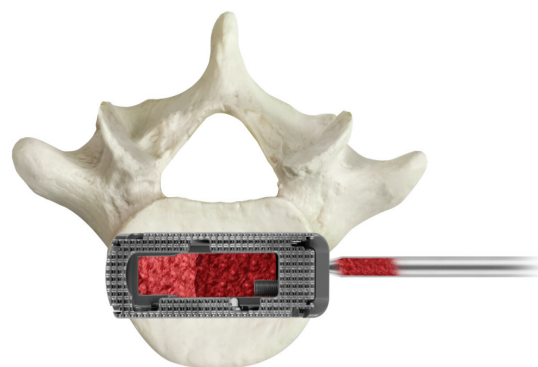


Figure 3: Additional bone graft may be packed into the graft chamber of the implant after expansion.

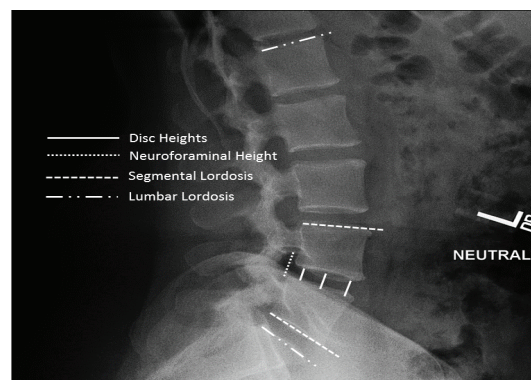


Figure 4: Standing lateral lumbar spine radiograph with superimposed lines displaying the measurements evaluated in this study. Measurements include disc heights, neuroforaminal height, segmental lordosis, and lumbar lordosis.

were 49.1% (28/57) female and 50.9% (29/57) male with an average age of 58 ± 12.3 years (range: 21-79 years). The average patients Charlson comorbidity index (CCI) score was 2.6 ± 1.9 (range: 0-8) (Table 1).

Surgical data

Of the 57 patients, 77.2% (44/57) underwent one-level and 22.8% (13/57) underwent two-level MIS LLIF, for a total of 70 spinal levels treated. Of the 70 levels, 45.7% (32/70) were instrumented at L4-L5 and 32.9% (23/70) at L3-L4. The average estimated blood loss was less than 50cc for one and two-level fusions with no blood transfusions. For one-level fusions, the mean operative time was 53.5 ± 11.0 min and 77.8 ± 21.5 min for two-level fusions. Mean fluoroscopic time was 27.1 ± 12.0 sec for one-level fusions and 29.8 ± 13.2 sec for two-level fusions. Mean length of hospital stay was 3.3 ± 2.0 days for one-level fusions and 4.4 ± 2.7 days for two-level fusions (Table 2).

Patient Reported Outcomes (VAS and ODI)

Mean VAS back pain scores significantly improved by 51.9% (4.2 ± 1.0), 60.5% (4.9 ± 1.2), 72.8% (5.8 ± 1.2), and 80.2% (6.5 ± 1.2) at 6 weeks, 3, 6, and 12 months, respectively (P<0.001) (Figure 5). Mean ODI scores significantly improved by 38.6% (29.9 ± 13.1 points), 55.1% (42.6 ± 12.2 points), 67.7% (52.4 ± 13.5 points), and 78.9% (61.1 ± 11.9 points) at 6 weeks, 3, 6, and 12 months, respectively (P<0.001) (Figure 6 and Table 3).

Radiographic parameters

Mean anterior disc height significantly improved by 92.2% (6.7 ± 3.0 mm), 82.8% (6.1 ± 3.0 mm), 78.1% (5.5 ± 3.0 mm), and 71.9% (4.5 ±

Parameters		Overall
Number of Patients		57
Sex	Female, n (%)	28 (49.1%)
	Male, n (%)	29 (50.9%)
Age, mean (SD, range)		58 (12.3) (21-79)
CCI, mean (SD, range)		2.6 (1.9) (0-8)

Table 1: Baseline characteristics.

Parameters	Overall percentage
Type of Surgery, n (%)	
One-level	44 (77.2%)
Two-level	13 (22.8%)
Levels Treated, n (%)	
L1-L2	4 (5.7%)
L2-L3	11 (15.7%)
L3-L4	23 (32.9%)
L4-L5	32 (45.7%)
Mean Estimated Blood Loss	
One-level	<50cc
Two-level	<50cc
Mean Operative Time, n (SD)	
One-level	53.5 (11.0)
Two-level	77.8 (21.5)
Mean Fluoroscopic Time, n (SD)	
One-level	27.1 (12.0)
Two-level	29.8 (13.2)
Mean Length of Hospital Stay, n (SD)	
One-level	3.3 (2.0)
Two-level	4.4 (2.7)

Table 2: MIS LLIF fusion procedure characteristics.

2.9 mm) at 6 weeks, 3, 6, and 12 months, respectively (P<0.001). Mean middle disc height significantly improved by 86.8% (5.9 ± 2.4 mm), 81.6% (5.3 ± 2.3 mm), 73.7% (5.0 ± 2.3 mm), and 68.4% (4.7 ± 2.4 mm) at 6 weeks, 3, 6, and 12 months, respectively (P<0.001). Mean posterior disc height significantly improved by 88.9% (4.0 ± 1.8 mm), 75.6% (3.4 ± 1.8 mm), 66.7% (3.0 ± 1.8 mm), and 57.8% (2.6 ± 1.9 mm) at 6 weeks, 3, 6, and 12 months, respectively (P<0.001). Mean neuroforaminal height significantly improved by 41.8% (5.9 ± 3.9 mm), 38.3% (5.4 ± 4.0 mm), 31.2% (4.4 ± 4.0 mm), and 26.2% (3.7 ± 3.9 mm) at 6 weeks, 3, 6, and 12 months, respectively (P<0.001). Mean segmental lordosis significantly improved by 102.1% (4.8 ± 3.3°), 93.6% (4.4 ± 3.1°), 87.2% (4.1 ± 3.1°), and 78.7% (3.8 ± 2.9°) at 6 weeks, 3, 6, and 12 months, respectively (P<0.001). Mean lumbar lordosis significantly improved by 18.3% (7.3 ± 8.8°), 15.5% (6.2 ± 8.4°), 14.3% (5.7 ± 8.7°), and 12.8% (5.1 ± 8.8°) at 6 weeks, 3, 6, and 12 months, respectively (P<0.001) (Table 4).

Complications

There were no reported implant-related complications, radiolucency, or subsidence. There was a 0% pseudoarthrosis rate by 12 month follow-up.

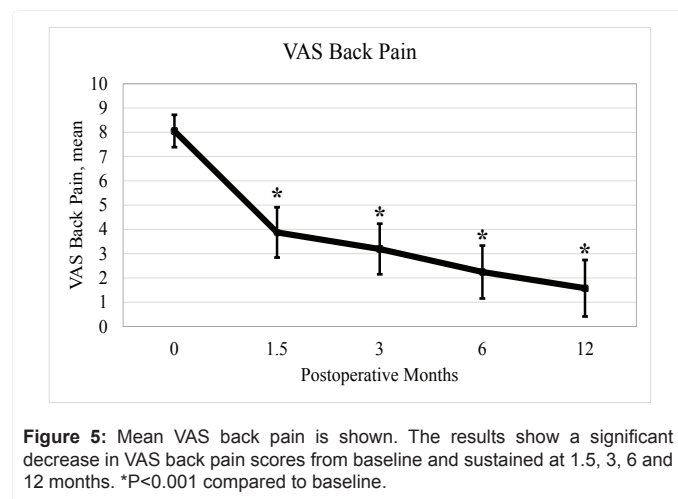


Figure 5: Mean VAS back pain is shown. The results show a significant decrease in VAS back pain scores from baseline and sustained at 1.5, 3, 6 and 12 months. *P<0.001 compared to baseline.

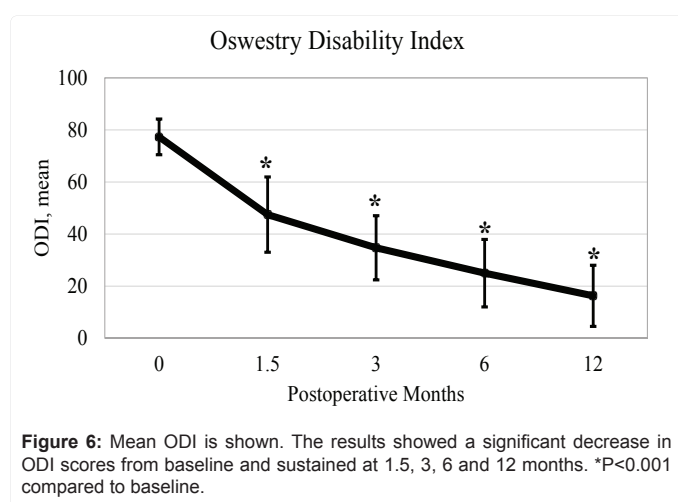


Figure 6: Mean ODI is shown. The results showed a significant decrease in ODI scores from baseline and sustained at 1.5, 3, 6 and 12 months. *P<0.001 compared to baseline.

Parameters	Baseline	6 Weeks	3 Months	6 Months	12 Months
VAS	8.1 (0.7)	3.9 (1.0)*	3.2 (1.0)*	2.2 (1.1)*	1.6 (1.2)*
ODI	77.3 (6.9)	47.5 (14.4)*	34.7 (12.3)*	25.0 (13.0)*	16.3 (11.7)*

*P<0.001 compared to baseline. Mean (SD).

Table 3: VAS back pain and ODI scores.

Parameters	Baseline	6 Weeks	3 Months	6 Months	12 Months
Anterior Disc Height	7.6 (3.1)	14.4 (2.2)*	13.8 (2.2)*	13.2 (2.0)*	12.8 (1.9)*
Middle Disc Height	6.4 (2.5)	12.3 (2.2)*	11.7 (2.4)*	11.4 (2.3)*	11.0 (2.2)*
Posterior Disc Height	4.5 (1.8)	8.5 (1.8)*	7.9 (1.6)*	7.5 (1.5)*	7.1 (1.6)*
Neuroforaminal Height	14.1 (4.1)	20.0 (3.8)*	19.5 (3.6)*	18.5 (3.4)*	17.8 (3.0)*
Segmental Lordosis	4.7 (2.9)	9.5 (3.4)*	9.1 (3.1)*	8.8 (3.0)*	8.4 (2.6)*
Lumbar Lordosis	39.9 (9.3)	47.2 (7.5)*	46.1 (6.5)*	45.6 (7.0)*	45.0 (7.0)*

*P<0.001 compared to baseline. Mean (SD).

Table 4: Radiographic parameters.

Discussion

Radiographic and clinical outcomes are essential to provide evidence on the use of expandable interbody spacers with adjustable lordosis for MIS LLIF. At 12-month follow-up, radiographic outcomes of this study showed that MIS LLIF using expandable interbody spacers with adjustable lordosis significantly corrected middle disc height and segmental lordosis by 68.4% and 78.7%, respectively. At 12-month follow-up, VAS back pain and ODI scores improved by three times the minimally clinical important difference (MCID) [11-15].

To the best of the authors' knowledge, this is the first study to describe the clinical and radiographic outcomes of the use of an expandable interbody spacer with an adjustable lordosis in MIS LLIF; therefore comparison to the literature is challenging. Sembrano and co-authors reported on the radiographic outcomes of patients who underwent LLIF comparing the use of non-lordotic versus lordotic interbody spacers [16]. Disc height and segmental lordosis were significantly increased by 74.2% and 22.4%, respectively. Lumbar lordosis decreased by 0.4%, but the change was not significant. No functional clinical outcomes were reported.

In other studies with expandable interbody spacers, the findings on radiographic and clinical outcomes were similarly improved. In 2016, Kim and co-authors reported on 50 patients using MIS expandable interbody spacers using a TLIF approach [17]. The study demonstrated maintenance of disc height in 1 and 2-level lumbar interbody fusions with no complications and no subsidence by 12 and 24-month follow-up. The findings underline the probable benefits of the use of expandable interbody spacers with regards to reduced subsidence rates, which is consistent with the current study. In a similar study, 54 patients underwent MIS and open lumbar fusion using the TLIF approach with 24-month follow-up [18]. The results indicate a low complication rate and short hospital stay while restoring and maintaining disc height, neuroforaminal height, and segmental lordosis.

The use of an adjustable lordotic expandable interbody spacer illustrates the potential for significant segmental correction within the sagittal plane, with a significant mean improvement of 3.7° of lordosis shown in this study at 12-month follow-up. Other studies on MIS TLIF have demonstrated 2-3° of segmental correction in the sagittal plane [17-19]. Additionally, the increase in segmental lordotic restoration in the current study compares favorably to a weighted average increase of 3.9° published in a review by Uribe and co-authors [20].

In the current study, the mean ODI was 47.5 ± 14.4, 34.7 ± 12.3, 25.0 ± 13.0, and 16.3 ± 11.7 at 6 weeks, 3, 6, and 12 months, respectively. Significant clinical benefit was achieved, with a mean ODI improvement of at least 20 points at each time interval: mean improvement of 29.8, 42.6, 52.3, and 61.0 points at 6 weeks, 3, 6, and 12 months, respectively [11-15].

Subsidence rates with the use of static interbody spacers have been reported to be relatively high. In a systematic review by Macki et al., the pooled subsidence rate with LLIF was 10.3% with a range of 0% to as high as 30% (n=141/1362 patients in 14 published articles) and reoperation rate for subsidence of 2.7% (n=41/1470 patients in 16 published articles) [21]. In addition, disc heights decreased by 5.6% at 3 months, 6.0% at 6 months, 10.2% at 12 months, to 8.9% at 24 months in a pooled analysis. In this review the studies with the highest subsidence rates were from Marchi et al., with a rate of 29.7% [22]. Marchi, Pimenta and Le et al. reported a subsidence rate of 17.2%, 16.6% and 14.3% respectively [23-25]. Static polymeric spacers of various sizes were used in these studies. In the current study, there was no subsidence reported.

Study Limitations

Although this is a single-surgeon single-site retrospective study with a small patient population, the results are consistent with findings from the literature. While this study only demonstrates 12-month follow-up, a long-term follow-up study is forthcoming.

Conclusion

This study provides clinical evidence that MIS LLIF using an expandable interbody spacer with adjustable lordosis is safe and effective at improving radiographic and clinical outcomes in the studied population. Disc height and lordosis were significantly restored, correcting sagittal alignment with no cases of subsidence up to 12-month follow-up. All clinical outcomes were significantly improved from preoperative values.

References

- Ozgun BM, Aryan HE, Pimenta L, Taylor WR (2006) Extreme Lateral Interbody Fusion (XLIF): a novel surgical technique for anterior lumbar interbody fusion. *Spine* J 6: 435-443.
- Lehmen JA, Gerber EJ (2012) MIS lateral spine surgery: a systematic literature review of complications, outcomes, and economics. *Eur Spine J* 3: 287-313.
- Kotwal S, Kawaguchi S, Lebl D, Hughes A, Huang R, et al. (2015) Minimally Invasive Lateral Lumbar Interbody Fusion: Clinical and Radiographic Outcome at a Minimum 2-year Follow-up. *J Spinal Disord Tech* 28: 119-125.
- Rodgers JA, Gerber EJ, Lehmen JA, Rodgers BW (2013) Clinical and Radiographic Outcome in Less Invasive Lumbar Fusion: XLIF at Two Year Follow-Up. *J Spine Neurosurg* 2: 1-6.
- Glassman SD, Bridwell K, Dimar JR, Horton W, Berven S, et al. (2005) The impact of positive sagittal balance in adult spinal deformity. *Spine (Phila Pa 1976)* 30: 2024-2029.
- Glassman SD, Berven S, Bridwell K, Horton W, Dimar JR (2005) Correlation of radiographic parameters and clinical symptoms in adult scoliosis. *Spine (Phila Pa 1976)* 30: 682-688.
- Djurasovic MO, Carreon LY, Glassman SD, Dimar JR 2nd, Puno RM, et al. (2008) Sagittal alignment as a risk factor for adjacent level degeneration: a case-control study. *Orthopedics* 31: 546.
- Chen WJ, Lai PL, Tai CL, Chen LH, Niu CC (2004) The effect of sagittal alignment on adjacent joint mobility after lumbar instrumentation—a biomechanical study of lumbar vertebrae in a porcine model. *Clin Biomech (Bristol, Avon)* 19: 763-768.
- Kumar MN, Baklanov A, Chopin D (2001) Correlation between sagittal plane changes and adjacent segment degeneration following lumbar spine fusion. *Eur Spine J*: 314-319.
- Godde S, Fritsch E, Dienst M, Kohn D (2003) Influence of cage geometry on sagittal alignment in instrumented posterior lumbar interbody fusion. *Spine (Phila Pa 1976)* 28: 1693-1699.
- Farrar JT, Young JP Jr, LaMoreaux L, Werth JL, Poole RM (2001) Clinical importance of changes in chronic pain intensity measured on an 11-point numerical pain rating scale. *Pain* 94: 149-158.
- Farrar JT, Portenoy RK, Berlin JA, Kinman JL, Strom BL (2000) Defining the clinically important difference in pain outcome measures. *Pain* 88: 287-294.

13. Beurskens AJ, de Vet HC, Koke AJ, van der Heijden GJ, Knipschild PG (1995) Measuring the functional status of patients with low back pain. Assessment of the quality of four disease-specific questionnaires. *Spine (Phila Pa 1976)* 20: 1017-1028.
14. Hagg O, Fritzell P, Nordwall A (2003) The clinical importance of changes in outcome scores after treatment for chronic low back pain. *Eur Spine J* 12: 12-20.
15. Fritz JM, Irrgang JJ (2001) A comparison of a modified Oswestry Low Back Pain Disability Questionnaire and the Quebec Back Pain Disability Scale. *Phys Ther* 81: 776-788.
16. Sembrano JN, Horazdovsky RD, Sharma AK, Yson SC, Santos ERG, et al. (2017) Do Lordotic Cages Provide Better Segmental Lordosis Versus Nonlordotic Cages in Lateral Lumbar Interbody Fusion (LLIF)? *Clinical spine surgery* 30: E338-E343.
17. Kim CW, Doerr TM, Luna IY, Joshua G, Shen SR, et al. (2016) Minimally Invasive Transforaminal Lumbar Interbody Fusion Using Expandable Technology: A Clinical and Radiographic Analysis of 50 Patients. *World neurosurg* 90: 228-235.
18. Boktor JG, Pockett RD, Verghese N (2018) The expandable transforaminal lumbar interbody fusion - Two years follow-up. *J Craniovertebr Junction Spine* 9: 50-55.
19. Le TV, Vivas AC, Dakwar E, Baaj AA, Uribe JS (2012) The effect of the retroperitoneal transpsoas minimally invasive lateral interbody fusion on segmental and regional lumbar lordosis. *Scientific World Journal* 2012: 516706.
20. Uribe JS, Myhre SL, Youssef JA (2016) Preservation or Restoration of Segmental and Regional Spinal Lordosis Using Minimally Invasive Interbody Fusion Techniques in Degenerative Lumbar Conditions: A Literature Review. *Spine (Phila Pa 1976)* 41 Suppl 8: S50-58.
21. Macki M, Anand SK, Surapaneni A, Park P, Chang V (2018) Subsidence Rates After Lateral Lumbar Interbody Fusion: A Systematic Review. *World neurosurg* 122: 599-606.
22. Marchi L, Abdala N, Oliveira L, Amaral R, Coutinho E, et al. (2013) Radiographic and clinical evaluation of cage subsidence after stand-alone lateral interbody fusion. *J Neurosurg Spine* 19: 110-118.
23. Marchi L, Abdala N, Oliveira L, Amaral R, Coutinho E, et al. (2012) Stand-alone lateral interbody fusion for the treatment of low-grade degenerative spondylolisthesis. *ScientificWorldJournal* 2012: 456346.
24. Pimenta L, Marchi L, Oliveira L, Coutinho E, Amaral R (2013) A prospective, randomized, controlled trial comparing radiographic and clinical outcomes between stand-alone lateral interbody lumbar fusion with either silicate calcium phosphate or rh-BMP2. *J Neurol Surg A Cent Eur Neurosurg* 74: 343-350.
25. Le TV, Baaj AA, Dakwar E, Burkett CJ, Murray G, et al. (2012) Subsidence of polyetheretherketone intervertebral cages in minimally invasive lateral retroperitoneal transpsoas lumbar interbody fusion. *Spine (Phila Pa 1976)* 37: 1268-1273.

This article was originally published in a special issue, [Minimally Invasive Spine Surgery -III](#) handled by Editor(s). Anthony T. Yeung, M.D. Clinical professor, University of New Mexico School of Medicine Associate Desert Institute for Spine Care, Phoenix, Arizona Executive director International Intradiscal therapy Society Phoenix, Arizona

PAGE INTENTIONALLY LEFT BLANK

PAGE INTENTIONALLY LEFT BLANK

