

Adjustable Lordotic Expandable Spacers: How Do They Compare to Traditional Static Spacers in Lateral Lumbar Interbody Fusion?

Yan Michael Li¹, Richard F. Frisch², Zheng Huang³, James Towner¹, Yan Icy Li¹, Amber L. Edsall^{4*} and Charles Ledonio⁴

¹Department of Neurosurgery and Oncology, University of Rochester Medical Center School of Medicine and Dentistry, Elmwood Ave, Rochester, P. R. China

²Department of Medicine, South-Eastern Spine Institute, 1106 Chuck Dawley Boulevard Suite, Mt. Pleasant, USA

³Department of Orthopaedics, Guanghua Hospital, Shanghai, P.R. China

⁴Department of Medicine, Musculoskeletal Education and Research Center (MERC), A Division of Globus Medical, General Armistead Avenue, Audubon, USA

Abstract

Introduction: Expandable interbody spacers with adjustable lordosis were designed to expand in situ and avoid complications such as endplate damage, excessive trialing and forceful impaction associated with static spacers. This study compares the clinical and radiographic two-year outcomes between patients treated with static or expandable interbody spacers with adjustable lordosis for Minimally Invasive Lateral Lumbar Interbody Fusion (MIS LLIF).

Methods: This is a retrospective, multi-site, multi-surgeon, Institutional Review Board-exempt chart review of patients who underwent MIS LLIF using either a static (27 patients) or expandable spacer with adjustable lordosis (66 patients). Radiographs, complications and patient-reported outcomes were collected and compared from preoperative up to 24-month postoperative follow-up.

Results: Mean improvement of Visual Analogue Scale back pain at 6, 12 and 24 months, as well as Oswestry Disability Index scores at 3, 6, 12, and 24 months, were significantly higher in the expandable group compared to the static group. The mean improvement of ODI scores from preoperative to 3, 6, 12, and 24 months was significantly greater in the expandable group by 55.6%, 75.6%, 77.4%, and 108.9% and by 48.2%, 34.6%, and 71.5% at 6, 12, and 24 months postoperatively for VAS pain scores, compared to the static group and ($p < 0.05$) Disc height mean improvement from preoperative to 24 months was more significant in the static group compared to the expandable group. Implant subsidence was significantly greater in the static group (18.5%, 5/27 patients) compared to the expandable group (0/66 patients) (all $p < 0.05$).

Conclusion: This study showed significant positive clinical and radiographic outcomes for patients who underwent MIS LLIF using static or expandable interbody spacers with adjustable lordosis. Both static and expandable groups demonstrated long-term maintenance of significant radiographic improvements, with minimal complications reported and sustained significant clinical improvements at 24-month follow-up. There was a 0% subsidence rate in the expandable group, compared to an 18.5% subsidence rate in the static group. The use of expandable spacers with adjustable lordosis was safe and effective for the studied patient population.

Keywords: Expandable spacers • Minimally invasive surgery • Lateral lumbar interbody fusion • Static spacers • Degenerative disc disease

Introduction

Minimally Invasive (MIS) surgical techniques have become more widespread in spinal surgery. Advantages of MIS surgery include less paraspinal musculature disruption, greater vertebral slip reduction, less blood loss, fewer complications, better maintenance of lumbar lordosis, and a lower cost per quality-adjusted life year compared to conventional open lumbar spine surgery [1-5]. Common surgical approaches include transforaminal lumbar interbody fusion, posterior lumbar interbody fusion, and anterior lumbar interbody fusion. Lateral Lumbar Interbody Fusion (LLIF) is a popular retroperitoneal transpoas approach that may help minimize the risk of complications associated with anterior and posterior lumbar interbody fusion techniques [5,6]. Static interbody

spacers may cause iatrogenic endplate damage from excessive trialing and forceful impaction which may increase the rate of implant subsidence [7-11]. Expandable interbody spacers with adjustable lordosis offer in situ expansion that may better restore disc height and segmental lordosis, allowing for optimal indirect decompression with minimal complications. The importance of restoring disc height and segmental lordosis in spinal arthrodesis has been well-established [12] and has been correlated with improved functional, clinical outcomes [13-15]. However, literature is sparse in long-term studies comparing the functional and radiographic outcomes of expandable vs static interbody spacers [16-24]. This study compares the clinical and radiographic outcomes between patients treated with PEEK static or titanium expandable interbody spacers with adjustable lordosis for MIS LLIF up to 24-months postoperatively.

Materials and Methods

This is a multi-site, multi-surgeon retrospective study from a prospectively collected cohort of patients who were diagnosed with symptomatic degenerative disc disease with or without Grade 1 spondylolisthesis in one or two contiguous levels, and who underwent MIS LLIF using a PEEK static interbody spacer with supplemental fixation, or with a novel titanium expandable interbody spacer with adjustable lordosis with supplemental fixation (RISE-AL®; Globus Medical, Inc., Audubon, PA, USA) (Figures 1 and 2). Patient demographics, Visual Analog Scale (VAS) back pain scores, Oswestry Disability Index (ODI)

*Address for Correspondence: Edsall AL, Department of Medicine, Musculoskeletal Education and Research Center (MERC), A Division of Globus Medical, General Armistead Avenue, Audubon, USA, E-mail: aedsall@globusmedical.com

Copyright: © 2020 Li YM, et al. This is an open-access article distributed under the terms of the Creative Commons Attribution License, which permits unrestricted use, distribution, and reproduction in any medium, provided the original author and source are credited.

Received 09 September 2020; Accepted 29 September 2020; Published 06 October 2020



Figure 1. Oblique view of the expandable interbody spacer with adjustable lordosis.

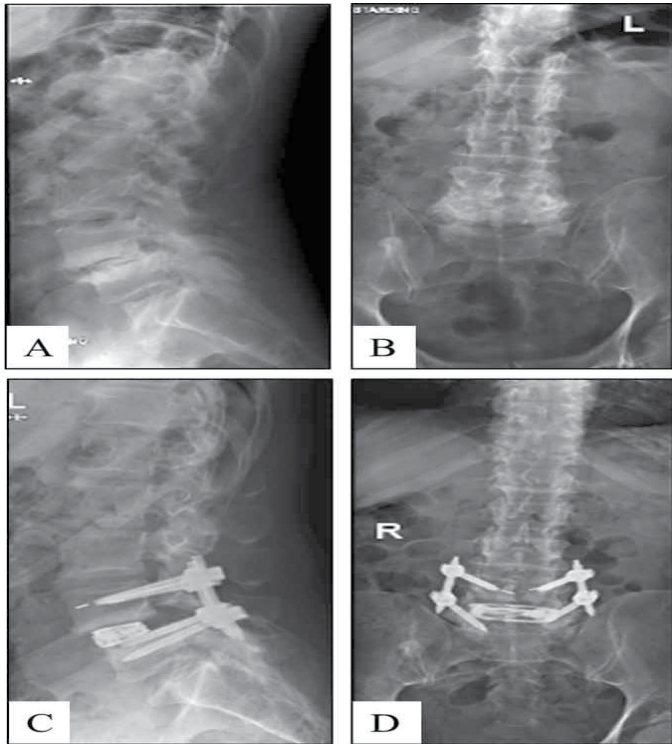


Figure 2. Preoperative lateral (A) and anteroposterior (B) radiographs and postoperative lateral (C) and anteroposterior (D) radiographs of a one-level MIS LLIF using an adjustable lordotic expandable interbody spacer at L4-L5.

scores, and radiographic parameters were collected at 6 weeks, 3, 6, 12, and 24 months postoperatively. Raw radiographic measurements were collected, reported, and analyzed. The difference between baseline and each time point per patient was calculated and reported as the “mean difference.” This was calculated to help minimize the effect of the difference in preoperative radiographic measurements between groups.

Surgical technique

After the induction of general anesthesia, patients were secured to the operating table with adhesive tape, placed in the lateral decubitus position. An oblique incision was made at the operative disc segment under fluoroscopic guidance, followed blunt dissection under direct visualization through the retroperitoneal space. The psoas muscle was exposed then palpated, after the retroperitoneal fat was first anteriorly mobilized. A second blunt dissection was performed down to the operative intervertebral disc level. Neuromonitoring stimulation was performed in the initial step and whenever relocation of retractors occurred and did not show any nerve conduction abnormalities (lumbar plexus) or signal changes. The appropriate vertebral level was confirmed via fluoroscopy then a minimally invasive retractor was docked, sequentially dilated and secured to the table-mounted arm followed by an annulotomy and then by a discectomy. Under fluoroscopic imaging, the endplates were decorticated and appropriately prepared.

Expandable group

For the expandable group, an expandable trial was used to allow for gradual distraction of the disc space. An expandable interbody spacer of appropriate size was selected, packed with autograft, and implanted laterally across the disc space. The spacer was then expanded to the desired height and backfilled with autograft (Figure 3). The expandable interbody spacer used in this study is manufactured from titanium alloy. The device is inserted at a contracted height and expanded in situ once correctly positioned within the intervertebral space, offering continuous expansion and adjustable lordosis for optimal endplate-to-endplate contact. Appropriate expansion was achieved via fluoroscopy and the tactile feel of the implant in the disc space. The overall height was determined through the 3 nm torque safety feature using a Lateral Torque-Limiting Driver by counting the number of revolutions of the driver (1 revolution equals 0.5 mm of expansion).

Static group

For the static group, distraction of the disc space occurred from sequential trialing. The smallest static trial was initially inserted into the disc space, progressing to larger trials as needed. A static interbody spacer of appropriate size was selected, packed with autograft, and implanted laterally across the disc space. The static interbody spacer used in this study is manufactured from PEEK radiolucent polymer with titanium alloy or tantalum markers, with a self-distracting leading edge for implant insertion.

Supplemental fixation

In both groups, pedicle screws and rods were used for supplemental fixation. Locking caps were set once the rods were in their proper position. Posterior decompression was performed for cases when LLIF did not increase preoperative disc height by more than double, or in cases of severe spinal stenosis with neurological deficit. Intraoperative fluoroscopy images were taken to verify screw and rod positions. Surgical incisions were cleaned and closed in the standard fashion.

Quantitative measurements

Radiographic lumbosacral parameters were measured on upright lateral radiographs using imaging software (Surgimap®; Globus Medical, Inc., Audubon, PA; Intellispace PACS 4.4©; Koninklijke Philips N.V, Amsterdam, Netherlands) (Figure 4). Measurements included disc height, neuroforaminal height, and segmental lordosis. Disc height was defined as the distance between the inferior and superior endplates at the middle portion of the vertebral body. Neuroforaminal height refers to the interpedicular height, or the rostral and caudal boundaries of the foramen. Segmental lordosis was measured as the Cobb angle of the superior endplate of the level below the LLIF and the inferior endplate of the level above the LLIF. Pseudoarthrosis and subsidence were assessed as previously described [25,26]. Subsidence was defined as a measured reduction in final follow-up disc height greater than 2 mm compared to disc height at 6 weeks postoperative [8]. Disc heights were measured from the middle portion of the endplates immediately above and below the referenced index levels on the lateral plane.

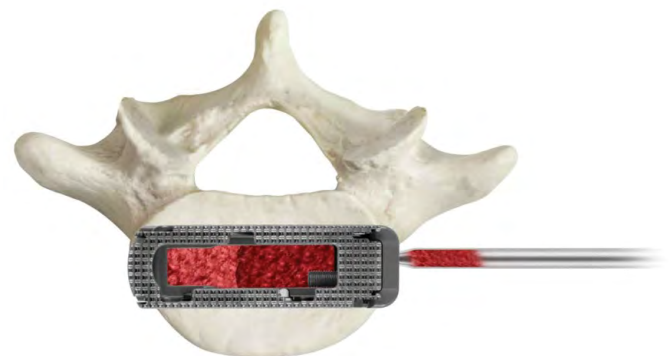

Figure 3. Additional bone graft material may be packed into the graft chamber of the implant after expansion.

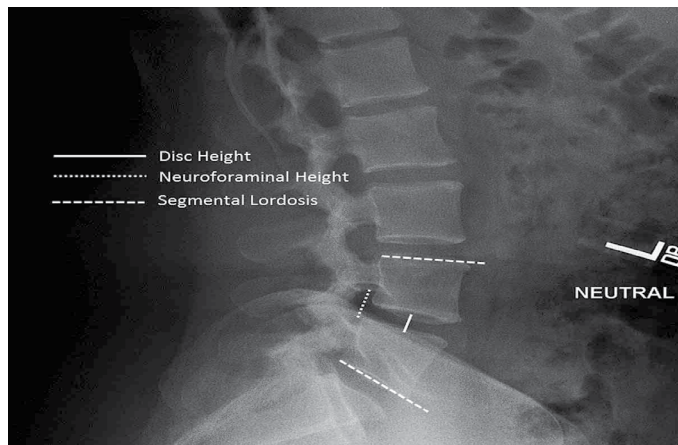


Figure 4. Standing lateral lumbar spine radiograph with superimposed lines displaying the measurements evaluated in this study, which include disc height, neuroforaminal height, and segmental lordosis.

Statistical analysis

The statistical analysis was performed using IBM® SPSS® Version 25 (IBM® Corp.; Armonk, NY, USA). Descriptive statistics for categorical data are presented as frequencies and percentages. Clinical and radiographic measurements are presented as means and standard deviations. Paired sample t-tests were used to compare patient outcomes from their preoperative values to each sequential postoperative follow-up measurement. Independent sample t-tests were used to compare quantitative data between study groups. Statistical significance was shown at $p < 0.05$.

Results

Patient demographics

A total of 66 consecutive patients underwent MIS LLIF from August 2016 to January 2017, and were implanted with a titanium expandable interbody spacer with adjustable lordosis. The patients were 47.0% (31/66) female and 53.0% (35/66) male, with an average age of 58.0 ± 12.1 (range: 21–82) years. A total of 27 consecutive patients underwent MIS LLIF from May 2014 to February 2016 and were implanted with a PEEK static interbody spacer. The patients were 74.1% (20/27) female and 25.9% (7/27) male, with an average age of 65.5 ± 9.3 years (range: 45–81 years) (Table 1).

Surgical data

Of the 66 patients in the expandable group, 80.3% (53/66) underwent one-level and 19.7% (13/66) underwent two-level MIS LLIF, for a total of 79 spinal levels treated. Of the 79 levels, 48.1% (38/79) were performed at L4–L5, and 32.9% (26/79) at L3–L4. Average estimated blood loss was minimal at 24.7 ± 13.6 cc for one-level fusions, and 30.8 ± 7.3 cc for two-level fusions with no blood transfusions. Mean operative time was 52.6 ± 10.7 min for one-level fusions, and 79.9 ± 20.8 min for two-level fusions. The mean length of hospital stay was 3.1 ± 2.0 days for one-level fusions and 4.5 ± 2.8 days for two-level fusions. Of the 27 patients implanted with the PEEK interbody spacer, 85.2% (23/27) underwent one-level and 14.8% (4/27) underwent two-level MIS LLIF, for a total of 31 spinal levels treated. Of those 31 levels, 61.3% (19/31) were performed at L4–L5, and 25.8% (8/31) at L3–L4. Average estimated blood loss was 40.2 ± 39.3 cc for one-level fusions, and 37.5 ± 25.0 cc for two-level fusions with no blood transfusions. Mean operative time was 66.9 ± 42.9 min for one-level fusions, and 74.5 ± 17.6 min for two-level fusions. The mean length of hospital stay was 2.1 ± 1.3 days for one-level fusions and 2.0 ± 1.4 days for two-level fusions (Table 2).

Patient-Reported Outcomes (VAS and ODI)

The mean preoperative VAS and ODI scores were significantly higher in the expandable group compared to the static group, with preoperative VAS and ODI scores being 8.0 ± 0.7 and 76.6 ± 7.3 points for the expandable group

versus 6.9 ± 2.3 and 46.9 ± 19.5 for the static group, respectively ($p < 0.05$). In the expandable group, mean VAS back pain scores significantly improved from baseline by 52.9% (4.2 ± 1.1 points), 61.2%, (4.9 ± 1.3 points), 72.6% (5.8 ± 1.2 points), 80.3% (6.4 ± 1.3 points), and 88.1% (7.1 ± 1.0 points) at 6 weeks, 3, 6, 12, and 24 months, respectively ($p < 0.001$). In the static group, mean VAS back pain scores significantly improved from baseline by 65.1% (4.5 ± 2.7 points), 68.7% (4.7 ± 2.8 points), 53.3% (3.6 ± 3.6 points), 65.9% (4.5 ± 2.9 points), and 50.4% (3.3 ± 3.3 points) at 6 weeks, 3, 6, 12, and 24 months, respectively ($p < 0.001$). For VAS back pain scores, the mean improvement from preoperative to 6, 12, and 24 months was significantly greater in the expandable group compared to the static group by 48.2%, 34.6%, and 71.5%, respectively ($p < 0.05$) (Figure 5). In the expandable group, mean ODI scores significantly improved from baseline by 41.3% (31.6 ± 13.5 points), 57.1% (43.7 ± 12.8), 69.6% (53.3 ± 13.4), 80.0% (61.3 ± 12.0), and 87.7% (67.2 ± 8.8) at 6 weeks, 3, 6, 12, and 24 months, respectively ($p < 0.001$). In the static group, mean ODI scores significantly improved from baseline by 43.3% (22.1

Table 1. Baseline characteristics.

Parameters	Expandable	Static
Number of Patients	66	27
Gender		
Female, n (%)	31 (47.0%)	20 (74.1%)
Male, n (%)	35 (53.0%)	7 (25.9%)
Age, mean \pm SD (range)	58.0 ± 12.1 (21–82)	65.5 ± 9.3 (45–81)

Table 2. MIS LLIF fusion procedure characteristics.

Parameters	Expandable	Static
Type of Surgery, n (%)		
One-level	53 (80.3%)	23 (85.2%)
Two-level	13 (19.7%)	4 (14.8%)
Levels Treated, n (%)		
L1–L2	4 (5.1%)	0 (0.0%)
L2–L3	11 (13.9%)	4 (12.9%)
L3–L4	26 (32.9%)	8 (25.8%)
L4–L5	38 (48.1%)	19 (61.3%)
Mean Estimated Blood Loss, Mean \pm SD		
One-level	24.7 ± 13.6	40.2 ± 39.3
Two-level	30.8 ± 7.3	37.5 ± 25.0
Mean Operative Time, Mean \pm SD		
One-level	52.6 ± 10.7	66.9 ± 42.9
Two-level	79.9 ± 20.8	74.5 ± 17.6
Mean Length of Hospital Stay, Mean \pm SD		
One-level	3.1 ± 2.0	2.1 ± 1.3
Two-level	4.5 ± 2.8	2.0 ± 1.4

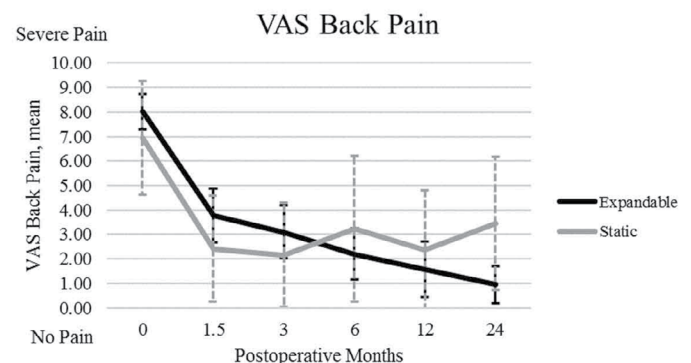


Figure 5. Mean VAS back pain is shown. The results show a significant decrease in VAS back and leg pain scores from baseline and sustained at 6 weeks, 3, 6, 12, and 24 months for the expandable group. Note the downward trend towards lower pain scores for the expandable group, and an upward trend for the static group.

± 26.6 points), 52.7% (24.7 ± 25.0), 51.3% (24.1 ± 24.1), 56.8% (27.1 ± 23.9), and 42.3% (19.8 ± 21.5) at 6 weeks, 3, 6, 12, and 24 months, respectively (p<0.001). For ODI scores comparing both groups, the mean improvement from preoperative to 3, 6, 12, and 24 months was significantly greater in the expandable group by 55.6%, 75.6%, 77.4%, and 108.9%, respectively, compared to the static group (p<0.05) (Figure 6).

Radiographic parameters

The mean preoperative segmental lordosis, disc height, and neuroforaminal height were significantly higher in the static group compared to the expandable group (p<0.05). Mean outcomes for each time point are presented in Table 3, and the mean improvements from preoperative are presented in Table 4. In the expandable group, mean disc height significantly improved from baseline by 89.4% (5.9 ± 2.4 mm), 82.1% (5.4 ± 2.3 mm), 76.9% (5.0 ± 2.3 mm), 72.0% (4.7 ± 2.3 mm), 61.7% (4.0 ± 2.3 mm) at 6 weeks, 3, 6, 12, and 24 months, respectively (p<0.001). In the static group, disc height significantly improved from baseline by 62.3% (5.3 ± 2.6 mm), 61.8% (5.3 ± 2.7 mm), 59.6% (5.1 ± 2.8 mm), 56.7% (4.9 ± 3.1 mm), and 73.4% (6.4 ± 2.9 mm) at 6 weeks, 3, 6, 12, and 24 months, respectively (p<0.001). (Note: the static group had the greatest increase of disc height at 24 months.) Explanation of this occurrence is due to patient drop-out and/or patients' reluctance to undergo X-rays at 24 months postoperative; 6 weeks, 3 and 6 months postoperatively all had complete data with measurements for all 31 (31/31) operated levels; at 12 months, 30/31 levels were included, and 28/31 levels had measurements that were available at 24 months postoperatively. The static group resulted in a significantly greater increase (average mean difference at 24 months of 6.41 ± 2.9 mm) in disc height by 45.3% from preoperative to 24 months compared to the expandable group (average mean difference at 24 months of 4.04 ± 2.3 mm) (p < 0.05).

The mean neuroforaminal height significantly improved from baseline in the

expandable group by 42.4% (6.1 ± 3.7 mm), 39.0% (5.6 ± 3.8 mm), 32.5% (4.6 ± 3.8 mm), 42.2% (3.9 ± 3.8 mm), and 22.8% (3.3 ± 3.8 mm) at 6 weeks, 3, 6, 12, and 24 months, respectively (p<0.001). Neuroforaminal height significantly improved from baseline in the static group by 16.5% (3.4 ± 3.3 mm), 14.2% (2.8 ± 4.0 mm), 10.8% (2.2 ± 3.2 mm), 14.0% (3.0 ± 4.4 mm), and 8.5% (1.8 ± 4.3 mm) at 6 weeks, 3, 6, 12, and 24 months, respectively (p < 0.05). The mean improvement in neuroforaminal height from preoperative to 6 weeks, 3 months, and 6 months was significantly greater in the expandable group compared to the static group (p<0.05). Mean segmental lordosis significantly improved from baseline in the expandable group by 112.3% (5.2 ± 2.8°), 104.0% (4.8 ± 3.3°), 97.3% (4.5 ± 3.3°), 89.0% (4.1 ± 3.2°), and 86.4% (4.0 ± 3.1°) at 6 weeks, 3, 6, 12, and 24 months, respectively (p<0.001). Mean segmental lordosis significantly improved from baseline in the static group by 9.5% (1.3 ± 5.1 mm), 10.0% (1.4 ± 5.2 mm), 7.5% (1.0 ± 5.8 mm), 4.2% (0.6 ± 4.4 mm), and 17.2% (2.5 ± 5.2 mm) at 6 weeks, 3, 6, 12, and 24 months, respectively (p<0.05). The mean improvement in segmental lordosis from preoperative to 6 weeks, 3, 6, and 12 months was significantly greater in the expandable group compared to the static group (p<0.05) (Tables 3 and 4).

Complications

There were no implant-related complications reported for the expandable or static groups. At 12-month follow-up, the static group had significantly higher subsidence rates, with no new cases of subsidence development between 12- and 24-month follow-up. In the expandable group, the subsidence rate was 0% (0/66 patients), which was significantly lower than the static group at 18.5% (5/27 patients) (p<0.05).

Discussion

Long-term radiographic and clinical outcomes are essential to demonstrate

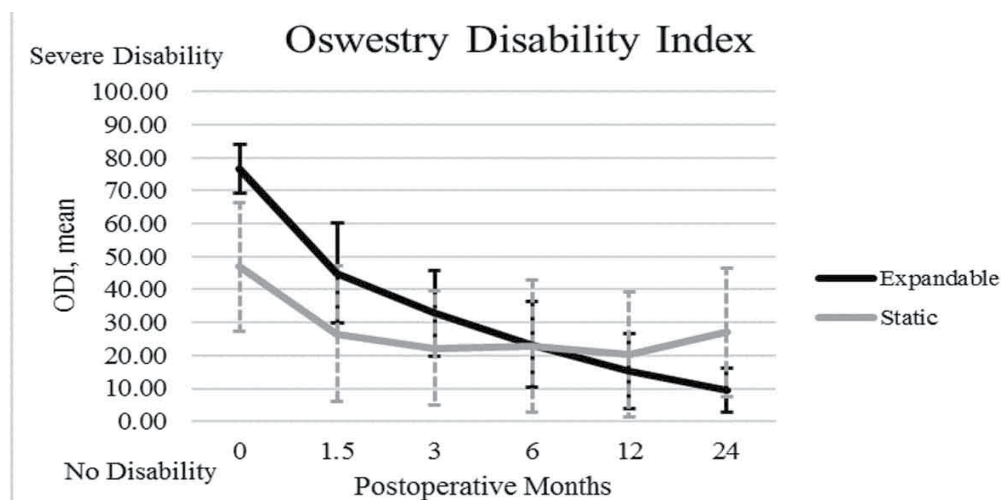


Figure 6. Mean ODI is shown. The results showed a significant decrease in ODI scores from baseline and sustained at 6 weeks, 3, 6, 12, and 24 months for the expandable group. Note the downward trend towards lower disability scores in the expandable group, and an upward trend in the static group.

Table 3. Mean values of patient reported outcomes and radiographic parameters.

Parameters	Device	Baseline	6 Weeks	3 Months	6 Months	12 Months	24 Months
VAS Back Pain	Expandable	8.0 ± 0.7	3.8 ± 1.1*	3.1 ± 1.1*	2.2 ± 1.1*	2.0 ± 1.1*	1.0 ± 0.8*
	Static	6.9 ± 2.3	2.4 ± 2.2*	2.2 ± 2.1*	3.2 ± 3.0*	2.4 ± 2.4*	3.4 ± 2.7*
ODI	Expandable	76.6 ± 7.3	45.0 ± 15.2*	32.9 ± 13.0*	23.3 ± 12.9*	15.3 ± 11.4*	9.4 ± 6.6*
	Static	46.9 ± 19.5	26.6 ± 20.5*	22.2 ± 17.4*	22.8 ± 20.2*	20.3 ± 19.0*	27.1 ± 19.5*
Middle Disc Height (mm)	Expandable	6.6 ± 2.6	12.4 ± 2.2*	11.9 ± 2.5*	11.6 ± 2.4*	11.3 ± 2.4*	10.6 ± 2.3*
	Static	8.6 ± 3.1	13.9 ± 2.3*	13.9 ± 2.7*	13.7 ± 2.7*	13.4 ± 3.0*	14.8 ± 2.2*
Neuroforaminal Height (mm)	Expandable	14.3 ± 4.1	20.3 ± 3.9*	19.8 ± 3.7*	18.9 ± 3.5*	18.2 ± 3.2*	17.5 ± 3.2*
	Static	20.3 ± 4.4	23.6 ± 3.7*	23.1 ± 3.5*	22.4 ± 3.7*	23.1 ± 3.5*	22.0 ± 3.3*
Segmental Lordosis (°)	Expandable	4.6 ± 3.4	9.8 ± 3.7*	9.4 ± 3.2*	9.1 ± 3.1*	8.7 ± 2.7*	8.6 ± 2.5*
	Static	14.8 ± 9.2	16.2 ± 8.1*	16.2 ± 8.7*	15.9 ± 8.4*	15.4 ± 9.0*	17.3 ± 9.6*

*p<0.05 compared to baseline. Mean ± SD

Table 4. Mean differences from baseline of patient reported outcomes and radiographic parameters.

Parameters	Device	6 Weeks	3 Months	6 Months	12 Months	24 Months
VAS Back Pain	Expandable	4.3 ± 1.1	4.9 ± 1.3	5.8 ± 1.2*	6.4 ± 1.3*	7.1 ± 1.0*
	Static	4.5 ± 2.7	4.7 ± 2.8	3.6 ± 3.6	4.5 ± 2.9	3.3 ± 3.3
ODI	Expandable	31.6 ± 13.5	43.7 ± 12.8*	53.3 ± 13.4*	61.3 ± 12.0*	67.2 ± 8.8*
	Static	22.1 ± 26.6	24.7 ± 25.0	24.1 ± 24.1	27.1 ± 23.9	19.8 ± 21.5
Middle Disc Height (mm)	Expandable	5.9 ± 2.4	5.4 ± 2.3	5.0 ± 2.3	4.7 ± 2.3	4.0 ± 2.3
	Static	5.3 ± 2.6	5.3 ± 2.7	5.1 ± 2.8	4.9 ± 3.1	6.4 ± 2.9†
Neuroforaminal Height (mm)	Expandable	6.1 ± 3.7*	5.6 ± 3.8*	4.6 ± 3.8*	3.9 ± 3.8	3.3 ± 3.8
	Static	3.4 ± 3.3	2.8 ± 4.0	2.2 ± 3.2	3.0 ± 4.4	1.8 ± 4.3
Segmental Lordosis (°)	Expandable	5.2 ± 2.8*	4.8 ± 3.3*	4.5 ± 3.3*	4.1 ± 3.2*	4.0 ± 3.2
	Static	1.3 ± 5.1	1.4 ± 5.2	1.0 ± 5.8	0.5 ± 4.4	2.5 ± 5.2

* $p < 0.05$ compared to static. † $p < 0.05$ compared to expandable. Mean ± SD

the durability, safety, and effectiveness of expandable interbody spacers with adjustable lordosis in LLIF compared to static interbody spacers. At 24-month follow-up, radiographic outcomes of this study showed that MIS LLIF using titanium expandable interbody spacers with adjustable lordosis significantly corrected neuroforaminal height and segmental lordosis by 22.8% and 86.4%, respectively, compared to an 8.5% increase in neuroforaminal height and a 17.2% increase in segmental lordosis observed with PEEK static interbody spacers. To the best of the authors' knowledge, this is the first study to describe the 24-month clinical and radiographic outcomes of the use of a titanium expandable interbody spacer with adjustable lordosis in MIS LLIF compared to static spacers; therefore, comparison to the literature is challenging. In a recent study, Frisch et al. reported on 27 patients who underwent LLIF with an expandable spacer without adjustable lordosis and 29 patients who underwent LLIF with a PEEK static spacer [27]. By 24 months, VAS back pain scores significantly improved by 3.1 points, while ODI scores significantly improved by 19.3 points. Neuroforaminal height at 6 weeks, 3, 6, 12, and 24 months all significantly improved compared to baseline. Segmental lordosis showed no significant changes at any of the time points compared to baseline. In the current study, VAS back pain scores significantly improved by 7.1 points, while ODI scores significantly improved by 67.2 points. Neuroforaminal height also significantly improved compared to baseline at 6 weeks, 3, 6, 12, and 24 months. Segmental lordosis significantly improved from baseline in the current study in all time points. Isaacs et al. reported on radiographic outcomes of patients who underwent MIS TLIF or MIS LLIF (NuVasive®, Inc., San Diego, CA, USA) with static interbody spacers in the treatment of degenerative spondylolisthesis with stenosis through 2-year follow-up [28]. Disc height significantly increased by 2.5 mm (32.9%) and 2.4 mm (35.8%) in the XLIF and MIS TLIF groups, respectively, from baseline to 24 months. Average disc angle (segmental lordosis) increased by 0.7° (8.2%) in the XLIF group and decreased by 0.3° (3.5%) in the TLIF group from baseline to 24 months.

In the current study, disc height resulted in a significant increase of 4.0 mm (61.7%), while segmental lordosis increased by 4.0° (86.4%) from baseline to 24 months, which was two to four times better than the previously cited reported outcome. Expandable titanium interbody spacers with adjustable lordosis may provide greater correction in the lumbar spine due to less endplate destruction and optimal fit after expansion compared to static interbody spacers. Isaacs et al. also reported on clinical outcomes [29]. VAS back pain scores significantly increased by 5.4 points in the XLIF group and 3.6 points in the TLIF group at 24 months. In the current study, VAS back pain scores significantly decreased by 7.1 points at 24 months. Subsidence rates with the use of static interbody spacers have been reported to be relatively high [7,9-11,27]. In a systematic review by Macki et al., the pooled subsidence rate with LLIF was 10.3% with a range of 0% to as high as 30% ($n=141/1362$ patients in 14 published articles) and a reoperation rate for subsidence of 2.7% ($n=41/1470$ patients in 16 published articles) [8]. In this review, the studies with the highest subsidence rates were from Marchi et al. (2013), with a rate of 29.7% [10]. Marchi et al. (2012), Pimenta et al., and Le et al. reported subsidence rates of 17.2%, 16.6% and 14.3%, respectively [7-11]. In a comparative study of static versus expandable interbody spacers with 2-year follow-up, Frisch et al. report a subsidence rate of 16.1% with the use of static polymeric spacers, although various sizes were used [27]. In the current study, there was no subsidence reported in the expandable group. MIS LLIF relies on indirect decompression

of the neural elements; therefore, subsidence is of particular concern for patients undergoing this approach.

Study Limitations

Although this is a retrospective study with a small patient population, with the static group having fewer patients than the expandable group, its results are consistent with findings from the literature. The groups compared in the study were reviewed at two different institutions, and the surgeons are from two different specialties [neurosurgery (RF) vs. orthopaedic surgery (YL)]. Yet, both surgeons utilized similar surgical techniques. Another limitation stemmed from different observers conducted the radiographic measurements. Preoperative radiographic measurements also differed between the two groups; however, comparing mean differences helped mitigate this heterogeneity. This study occurred in different time frames (2014-2016 vs. 2016-2017), which could raise the suspicion of a learning curve. However, author YL (2016-2017) had years of previous practice with the novel expandable technology, and thus, the patients in his cohort were not subjected to a learning curve from the surgeon; nor were the patients of RF using the older technology of the static cages in 2014-2016. According to Obrebsky et al. a well-executed orthopaedic study of this nature includes a comparison to a cohort, a patient population for which a standard treatment protocol is used, a follow-up rate of >80%, and follow-up of patients at specified time intervals, all of which this study has met [30]. This study forms the foundation for future studies with a higher level of evidence. Comparative studies with larger sample sizes and longer follow-up are needed

Conclusion

This study showed significant positive clinical outcomes for patients who underwent MIS LLIF using titanium expandable interbody spacers with adjustable lordosis, based on significant improvements in VAS pain and ODI scores at 24-month follow-up compared to the PEEK static group. Both static and expandable spacers increase disc height, neuroforaminal height, and segmental lordosis through 24-month follow-up. There was no subsidence in the expandable group, compared to a 18.5% subsidence rate in the static group. In this cohort, expandable spacers are safe, durable, and efficient when used in conjunction with MIS LLIF.

References

1. Su Kai, Jiyao Luan, Qingde Wang and Yong Yang, et al. "Radiographic Analysis of Minimally Invasive Transforaminal Lumbar Interbody Fusion versus Conventional Open Surgery on Sagittal Lumbar-Pelvic Alignment for Degenerative Spondylolisthesis." *World Neurosurg* 19 (2019): 30081-30086.
2. Kim, Yongjung Jones, Lawrence G Lenke and Gene Cheh, et al. "Evaluation of Pedicle Screw Placement in the Deformed Spine using Intraoperative Plain Radiographs: A Comparison with Computerized Tomography." *Spine* 30 (2005): 2084-2088.

3. Stevens, Kathryn James, David B Spenciner and Karen L Griffiths, et al. "Comparison of Minimally Invasive and Conventional Open Posterolateral Lumbar Fusion using Magnetic Resonance Imaging and Retraction Pressure Studies." *J Spinal Dis Tech* 19 (2006): 77-86.
4. Zhu, Hai-Feng, Gang-Liang Wang and Zhi-Jie Zhou, et al. "Prospective Study of Long-Term Effect between Multifidus Muscle Bundle and Conventional Open Approach in One-Level Posterior Lumbar Interbody Fusion." *Orthop Surg* 10 (2018): 296-305.
5. Lehmen, Jeff Ahn and Edward J Gerber. "MIS Lateral Spine Surgery: A Systematic Literature Review of Complications, Outcomes, and Economics." *Euro Spine J* 24 (2015): 287-313.
6. Kotwal, Suhel, Satoshi Kawaguchi and Darren Lebl, et al. "Minimally Invasive Lateral Lumbar Interbody Fusion: Clinical and Radiographic Outcome at a Minimum 2-Year Follow-Up." *J Spinal Dis Tech* 28 (2015): 119-125.
7. Le Tien, Ali A. Baaj, Elias Dakwar and Clinton J Burkett, et al. "Subsidence of Polyetheretherketone Intervertebral Cages in Minimally Invasive Lateral Retroperitoneal Transposas Lumbar Interbody Fusion." *Spine* 37 (2012): 1268-1273.
8. Macki Mohamed, Sharath Kumar Anand, Ashwin Surapaneni and Paul Park, et al. "Subsidence Rates after Lateral Lumbar Interbody Fusion: A Systematic Review." *World Neurosurg* 122 (2019): 599-606.
9. Marchi Luis, Nitamar Abdala, Leonardo Oliveira and Rodrigo Amaral, et al. "Stand-Alone Lateral Interbody Fusion for the Treatment of Low-Grade Degenerative Spondylolisthesis." *Sci World J* 22 (2012): 456346.
10. Marchi Luis, Nitamar Abdala, Leonardo Oliveira and Rodrigo Amaral, et al. "Radiographic and Clinical Evaluation of Cage Subsidence after Stand-Alone Lateral Interbody Fusion." *J Neurosurg Spine* 19 (2013): 110-118.
11. Pimenta Luiz, Luis Marchi, Leonardo Oliveira, and Etevaldo Coutinho, et al. "A Prospective, Randomized, Controlled Trial Comparing Radiographic and Clinical Outcomes between Stand-Alone Lateral Interbody Lumbar Fusion with Either Silicate Calcium Phosphate or rh-BMP2." *J Neurolog Surg* 74 (2013): 343-350.
12. Jang Jee-Soo, Sang-Ho Lee, Jun-hong Min, and Dae Hyeon Maeng. "Changes in Sagittal Alignment after Restoration of Lower Lumbar Lordosis in Patients with Degenerative Flat Back Syndrome." *J Neurosurg Spine* 7 (2007): 387-392.
13. Lazennec Jan, Sri Ramaré and Nor Arafati. "Sagittal Alignment in Lumbosacral Fusion: Relations between Radiological Parameters and Pain." *Euro Spine J* 9 (2000): 47-55.
14. Liang Yun, Weibin Shi, Chun Jiang and Zixian Chen, et al. "Clinical Outcomes and Sagittal Alignment of Single-Level Unilateral Instrumented Transforaminal Lumbar Interbody Fusion with a 4 to 5-Year Follow-Up." *Euro Spine J* 24 (2015): 2560-2566.
15. Schwab Frank, Vinson A. Smith, Michele Biserni and Lorenzo Gamez, et al. "Adult Scoliosis: A Quantitative Radiographic and Clinical Analysis." *Spine* 27 (2002): 387-392.
16. Alimi Marjan, Benjamin Shin, Michael Macielak and Christoph P. Hofstetter, et al. "Expandable Polyaryl-Ether-Ether-Ketone Spacers for Interbody Distraction in the Lumbar Spine." *Global Spine J* 5 (2015): 169-178.
17. Kim Shin Jae, Young Seok Lee, Young Baeg Kim and Seung Won Park, et al. "Clinical and Radiological Outcomes of a New Cage for Direct Lateral Lumbar Interbody Fusion." *Korean J Spine* 11 (2014): 145-151.
18. Park Jin Hoon, Chae Wan Bae, Sang Ryong Jeon and Seung Chul Rhim, et al. "Clinical and Radiological Outcomes of Unilateral Facetectomy and Interbody Fusion using Expandable Cages for Lumbosacral Foraminal Stenosis." *J Korean Neurosurg Soc* 48 (2010): 496-500.
19. Bhatia Nitin, Kenneth H. Lee, Christopher NH Bui and Mario Luna, et al. "Biomechanical Evaluation of an Expandable Cage in Single-Segment Posterior Lumbar Interbody Fusion." *Spine* 37 (2012): 79-85.
20. Folman Yoram, Sang-Ho Lee, Jose Raul Silvera and Reuven Gepstein. "Posterior Lumbar Interbody Fusion for Degenerative Disc Disease using a Minimally Invasive B-twin Expandable Spinal Spacer: A Multicenter Study." *J Spinal Dis Tech* 16 (2003): 455-460.
21. Zheng XiuJun, Rahul Chaudhari, Chunhui Wu and Amir A Mehbod, et al. "Biomechanical evaluation of an Expandable Meshed Bag Augmented with Pedicle or Facet Screws for Percutaneous Lumbar Interbody Fusion." *Spine J* 10 (2010): 987-993.
22. Qandah A. Nicholas, Noelle F. Klocke, Jordan J. Synkowski and Suresh R. Chinthakunta, et al. "Additional Sagittal Correction can be Obtained When using an Expandable Titanium Interbody Device in Lumbar Smith-Peterson Osteotomies: A Biomechanical Study." *Spine J* 15 (2015): 506-513.
23. Mantell Matthew, Mathew Cyriac, Colin M Haines and Manasa Gudipally, et al. "Biomechanical Analysis of an Expandable Lateral Cage and a Static Transforaminal Lumbar Interbody Fusion Cage with Posterior Instrumentation in an *in-vitro* Spondylolisthesis Model." *J Neurosurg Spine* 24 (2016): 32-38.
24. Gonzalez-Blohm, Sabrina Aura, James J Doulgeris and Kamran Aghayev, et al. "*In-vitro* Evaluation of a Lateral Expandable Cage and its Comparison with a Static Device for Lumbar Interbody Fusion: A Biomechanical Investigation." *J Neurosurg Spine* 20 (2014): 387-395.
25. Kanemura Tokumi, Akiyuki Matsumoto, Yoshimoto Ishikawa and Hidetoshi Yamaguchi, et al. "Radiographic Changes in Patients with Pseudarthrosis after Posterior Lumbar Interbody Arthrodesis using Carbon Interbody Cages: A Prospective Five-Year Study." *J Bone Joint Surg* 96 (2014): e82.
26. Choi Jae Young and Kyeong Hoon Sung. "Subsidence after Anterior Lumbar Interbody Fusion using Paired Stand-Alone Rectangular Cages." *Euro Spine J* 15 (2006): 16-22.
27. Frisch F. Richard, Ingrid Y. Luna, Daina M. Brooks, and Gita Joshua, et al. "Clinical and Radiographic Analysis of Expandable versus Static Lateral Lumbar Interbody Fusion Devices with Two-Year Follow-Up." *J Spine Surg* 4 (2018): 62-71.
28. Isaacs E. Robert, Jonathan N. Sembrano, Antoine G. Tohmeh. "Two-Year Comparative Outcomes of MIS Lateral and MIS Transforaminal Interbody Fusion in the Treatment of Degenerative Spondylolisthesis: Part II: Radiographic Findings." *Spine* 41 (2016): S133-44.
29. Sembrano N. Jonathan, Antoine Tohmeh and Robert Isaacs. "Two-Year Comparative Outcomes of MIS Lateral and MIS Transforaminal Interbody Fusion in the Treatment of Degenerative Spondylolisthesis: Part I: Clinical Findings." *Spine* 41 (2016): 123-132.
30. Obremskey T. William, Nick Pappas, Emad Attallah-Wasif and Paul Tornetta, et al. "Level of Evidence in Orthopaedic Journals." *J Bone Joint Surg* 87 (2005): 2632-2638.

How to cite this article: Yan Michael Li, Richard F. Frisch, Zheng Huang, and James Towner, et al. "Adjustable Lordotic Expandable Spacers: How Do They Compare to Traditional Static Spacers in Lateral Lumbar Interbody Fusion?" *J Spine* 9 (2020): 459. DOI: 10.37421/jsp.2020.9.459

PAGE INTENTIONALLY LEFT BLANK

